

Hepatic angiosarcoma in a patient treated with obeticholic acid for primary biliary cholangitis

Arif A. Arif¹, Subin Punnen², Michael Bleszynski², Daniel R. Owen³, Eric M. Yoshida^{1,4}

¹Department of Medicine, University of British Columbia, Vancouver BC, Canada; ²Department of Surgery, University of British Columbia, Vancouver BC, Canada; ³Department of Pathology and Laboratory Medicine, University of British Columbia, Vancouver BC Canada; ⁴Division of Gastroenterology, University of British Columbia, Vancouver General Hospital, Vancouver BC, Canada

Abstract

Primary Biliary Cholangitis (PBC) is a chronic cholestatic liver disease that can lead to cirrhosis and the development of hepatocellular carcinoma. PBC is not known to be associated with hepatic angiosarcoma. Second-line treatments for PBC, including obeticholic acid, have had less than a decade of clinical use. We present a case of a patient with PBC treated with obeticholic acid who subsequently developed hepatic angiosarcoma. The patient is now on active surveillance following resection of the angiosarcoma. The development of this rare and aggressive cancer should prompt closer post-marketing surveillance for obeticholic acid.

Keywords: Hepatic angiosarcoma; primary biliary cholangitis; obeticholic acid.

Introduction

Primary biliary cholangitis (PBC) is an autoimmune chronic cholestatic liver disease with a variable rate of progression to cirrhosis^[1,2] and is a risk factor for hepatocellular carcinoma.^[3] The standard of care for treatment of PBC is ursodeoxycholic acid (UDCA), which improves serum liver tests and transplant-free survival.^[4] However, in roughly 20%–40% of patients with PBC, there is an insufficient response to UDCA, which is associated with lower rates of transplant-free survival and increased rates of hepatocellular carcinoma.^[4] Since the mid-2010s, obeticholic acid (OCA), a farnesoid X receptor agonist, has shown efficacy as a second-line therapy for PBC.^[5,6]

Hepatic angiosarcoma is a rare but aggressive malignancy of vascular origin. It is not currently believed that PBC or cirrhosis are risk factors for hepatic angiosarcoma.^[7] Here, we present a case of hepatic angiosarcoma in a patient with PBC who received OCA.

How to cite this article: Arif AA, Punnen S, Bleszynski M, Owen DR, Yoshida EM. Hepatic angiosarcoma in a patient treated with obeticholic acid for primary biliary cholangitis. *Hepatology Forum* 2024; 0(0):0–0.

Received: October 03, 2024; **Revised:** November 07, 2024; **Accepted:** December 02, 2024; **Available online:** December 24, 2024

Corresponding author: Eric M. Yoshida; Department of Medicine, University of British Columbia, Vancouver BC, Canada

Phone: +1 604-875-5371; **e-mail:** Eric.Yoshida@vch.ca



OPEN ACCESS
This work is licensed under a Creative Commons Attribution-NonCommercial 4.0 International License.

Hepatology Forum - Available online at www.hepatologyforum.org

Case Report

A 53-year-old man of Caucasian descent with a 16-year history of PBC has been managed with ursodeoxycholic acid (UDCA) 500 mg twice daily for years. For the past two years, he has had a persistent, cholestatic pattern of liver enzyme elevation, which prompted the addition of OCA to his treatment regimen. His past medical history includes polymyositis (well-controlled on mycophenolate and intravenous immunoglobulin), asymptomatic bicuspid aortic valve disease, hypothyroidism, hypertension, and renal cell carcinoma (resected in 2019).

Prior to the initiation of OCA, he had an alkaline phosphatase of 380 U/L, a gamma-glutamyl transferase of 185 U/L, an alanine aminotransferase of 60 U/L, an aspartate aminotransferase of 55 U/L, and a normal bilirubin level. He was initiated on 5 mg of OCA daily. His OCA dose was briefly increased to 10 mg, which caused intolerable pruritus. Subsequently, his OCA dose was maintained at 5 mg, with some reduction in his liver enzymes (Table 1). He was maintained on OCA for two years. His FibroScan® (Echosens) transient elastography showed a liver stiffness of 7.6 kPa, correlating to pre-cirrhotic (F1–F2) stage liver fibrosis.

A CT scan of the abdomen, requested to follow up on a known kidney nodule for renal cell carcinoma monitoring, incidentally identified a new mass (6.2×4.1×5.8 cm) in liver segment IV. The liver mass was hypo-enhancing, with ill-defined margins and overlying capsular retraction (Fig. 1). The liver mass developed rapidly; it was not present on a CT scan nine months prior. The mass was diagnosed as hepatic angiosarcoma by pathologic assessment of a percutaneous liver biopsy. The diagnosis was confirmed by immunohistochemistry, showing strong positivity for vascular markers (ERG and CD31) and negativity for markers of metastatic carcinoma (including renal cell carcinoma), primary liver carcinoma, metastatic melanoma, and other forms of sarcoma. Gene fusion testing using a pan-sarcoma fusion assay (NanoString) was negative for pathologic gene fusions.

A staging CT scan of the chest, abdomen, and pelvis conducted two months later did not reveal any metastatic lesions; however, the angiosarcoma had interval growth to 8.2×5.7×7.8 cm. Given the isolated nature of the disease and the patient being a good candidate for upfront resection, an uncomplicated open segment 4b/5 hepatectomy with portal lymphadenectomy was performed approximately 12 weeks after diagnosis.

The diagnosis of epithelioid angiosarcoma, measuring 13.9 cm, was re-confirmed by pathologic examination of the surgical resection specimen (Fig. 2). Microscopic assessment also confirmed a negative surgical resection margin (R0) and five benign periportal lymph nodes. The patient was not offered adjuvant chemotherapy. He continues active

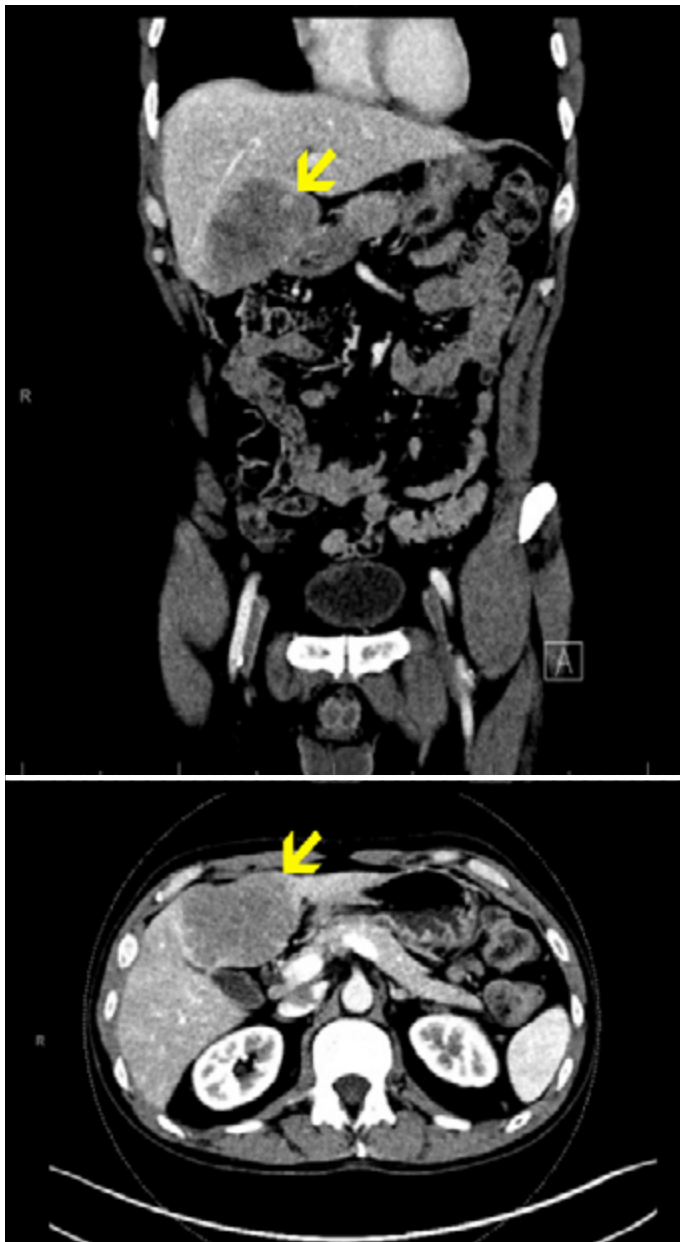


Figure 1. Computed tomography images of the abdomen and pelvis identifying a segment IV hypoattenuating liver mass measuring 6.2 x 4.1 x 5.8 cm with ill-defined margins and overlying capsular retraction.

surveillance with a plan for CT imaging every three months for the first two years, for a total of five years of surveillance. No evidence of recurrence has been observed in the first six months of follow-up. The patient continues UDCA monotherapy for PBC. None of the usual risk factors for angiosarcoma were identified in a thorough review of the patient's history.

Discussion

OCA is becoming established as a second-line therapy for PBC since the completion of phase 3 placebo-controlled trials in 2016.^[5] Both PBC and hepatic angiosarcoma have been individually described in the literature for over 50 years;^[7,8] however, their co-occurrence has

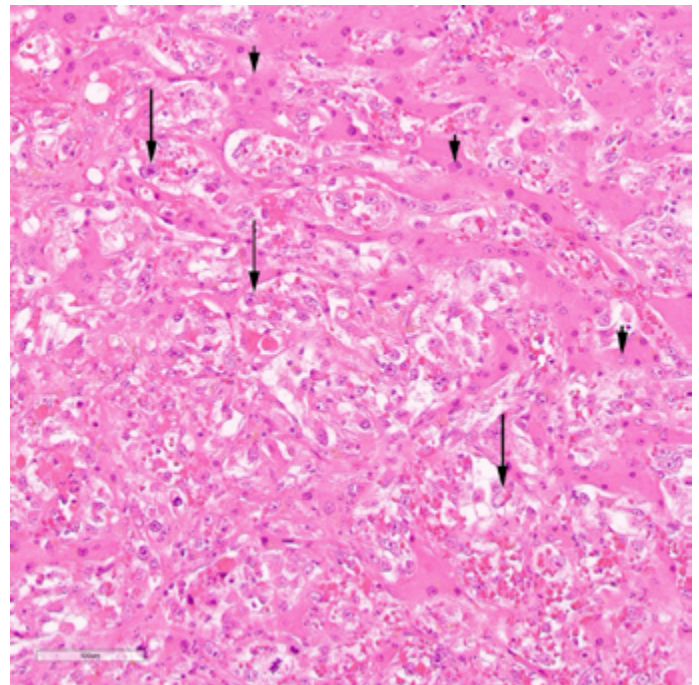


Figure 2. Surgical resection of liver mass containing hepatic angiosarcoma (long arrows) infiltrating hepatic sinusoids. Short arrows indicate background benign hepatocytes. H&E, 200X original magnification.

Table 1. Patient liver tests before and 12 months after initiating treatment with 5 mg obeticholic acid

Liver test	Pre-obeticholic acid	12 mo. obeticholic acid
ALP (ULN*=136)	380	252
ALT (ULN=55)	60	26
AST (ULN=38)	55	42
GGT (ULN=73)	185	86
Bilirubin (ULN=20)	8	6

All liver enzyme values are in units per liter, bilirubin units are in micromoles per liter. *ULN: Upper limit of normal.

not been reported until recently, in a Chinese-language journal that is not indexed Zhao et al.^[9] Herein, we report the second case of hepatic angiosarcoma occurring in a patient with PBC and the first case associated with OCA.

Hepatic angiosarcoma received public attention after being linked to industrial exposure to vinyl chloride, with a wide exposure range of 4–27 years.^[10] Since then, several exposures have been associated with hepatic angiosarcoma, including iatrogenic exposure to radiocontrast colloidal thorium dioxide and chronic arsenic exposure, among others. Hepatic angiosarcoma has also been reported in association with cyclophosphamide and androgenic steroids.^[7]

Chronic liver disease leading to cirrhosis causes an inflammatory and pro-fibrotic environment, well-known to increase the risk of hepatocellular carcinoma and cholangiocarcinoma.^[3] However, there is no established link between cirrhosis-associated chronic liver disease and hepatic angiosarcoma. Despite the high prevalence of cirrhosis, only a

single case of hepatic angiosarcoma in a patient with pre-existing cirrhosis has been reported.^[11] Although the increased incidence of hepatic angiosarcoma related to vinyl chloride may have declined since its first description in 1974,^[12] workers exposed to vinyl chloride remain the subject of investigation. A 2021 study of plasma metabolomics in these workers found the top affected pathway included specific metabolites of bile acids, and serum bile acids were useful biomarkers in identifying vinyl chloride hepatotoxicity.^[13] We hypothesize that aberrant bile acid metabolism induced by OCA may be a pathogenic mechanism in hepatic angiosarcoma.

The advent of several second-line agents for the treatment of PBC, including OCA, has been an important recent advancement. However, OCA, which may fundamentally alter hepatic bile acid metabolism, has had limited exposure time in humans. Ongoing long-term safety studies and post-marketing surveillance are critical in identifying relatively rare events such as hepatic angiosarcoma.

Conclusion

This is the second reported case of hepatic angiosarcoma in a patient with PBC and the first reported case of hepatic angiosarcoma associated with OCA. Bile acid metabolism may be an important element in the pathogenesis of hepatic angiosarcoma. As we approach approximately a decade of experience with OCA and with the advent of other second-line agents, it is important to continue surveillance for hepatic angiosarcoma.

Author Contributions: Concept – EMY; Design – AAA, EMY, SP, MB, DRO; Supervision – EMY; Data Collection and/or Processing – AAA, DRO, EMY; Analysis and/or Interpretation – AAA, EMY, SP, MB, DRO; Literature Search – AAA, EMY; Writing – AAA, EMY, SP, MB, DRO; Critical Reviews – AAA, EMY, SP, MB, DRO.

Conflict of Interest: Dr. Eric Yoshida has been an investigator of clinical trials sponsored by Intercept Inc, Paladin Labs, Gilead Sciences, and Pfizer.

Informed Consent: Written informed consent was obtained from the patient for the publication of the case report and the accompanying images.

Use of AI for Writing Assistance: Not declared.

Financial Disclosure: The authors declared that this study has received no financial support.

Peer-review: Externally peer-reviewed.

References

1. Gulamhusein AF, Hirschfield GM. Primary biliary cholangitis: pathogenesis and therapeutic opportunities. *Nat Rev Gastroenterol Hepatol* 2020;17(2):93-110.
2. Ergenc I, Gozaydinoglu B, Keklikkiran C, Yilmaz Y. The risk of development of primary biliary cholangitis among incidental antimitochondrial M2 antibody-positive patients. *Hepatol Forum* 2023;4(2):69-73.
3. Schönau J, Wester A, Schattenberg JM, Hagström H. Risk of cancer and subsequent mortality in primary biliary cholangitis: A population-based cohort study of 3052 Patients. *Gastro Hep Adv* 2023;2(7):879-888.
4. Lammers WJ, Hirschfield GM, Corpechot C, Nevens F, Lindor KD, Janssen HL, et al; Global PBC Study Group. Development and validation of a scoring system to predict outcomes of patients with primary biliary cirrhosis receiving ursodeoxycholic acid therapy. *Gastroenterology* 2015;149(7):1804-1812.e4.
5. Nevens F, Andreone P, Mazzella G, Strasser SI, Bowlus C, Invernizzi P, et al; POISE Study Group. A placebo-controlled trial of obeticholic acid in primary biliary cholangitis. *N Engl J Med* 2016;375(7):631-643.
6. Barba Bernal R, Ferrigno B, Medina Morales E, Castro CM, Goyes D, Trivedi H, Patwardhan VR, Bonder A. Management of Primary Biliary Cholangitis: Current Treatment and Future Perspectives. *Turk J Gastroenterol* 2023;34(2):89-100.
7. Rojas S, Rey Chaves CE, Robledo S, Conde D, Sabogal Olarte JC. Primary hepatic angiosarcoma: a systematic review. *Ann Med Surg (Lond)* 2024;86(3):1601-1605.
8. Dauphinee JA, Sinclair JC. Primary biliary cirrhosis. *Can Med Assoc J* 1949;61(1):1-6.
9. Zhao J, Chen Z, Ding C, Yuan L, Qian J, Xu C, et al. Primary biliary cholangitis with hepatic angiosarcoma: a case report. *J Clin Hepatol* 2021;37:2411-2413.
10. Mark L, Delmore F, Creech JL Jr, Ogden LL II, Fadell EH, Songster CL, et al. Clinical and morphologic features of hepatic angiosarcoma in vinyl chloride workers. *Cancer* 1976;37(1):149-163.
11. Sánchez Rodríguez E, Pinilla Pagnon I, Ríos Leon R, González-Olivares CG, Martín-Mateos RM, Albillos A. Hepatic angiosarcoma in a patient with liver cirrhosis. *Gastroenterol Hepatol* 2019;42(5):304-305. [English, Spanish]
12. Collins JJ, Jammer B, Sladeczek FM, Bodnar CM, Salomon SS. Surveillance for angiosarcoma of the liver among vinyl chloride workers. *J Occup Environ Med* 2014;56(11):1207-1209.
13. Guardiola JJ, Hardesty JE, Beier JJ, Prough RA, McClain CJ, Cave MC. Plasma metabolomics analysis of polyvinyl chloride workers identifies altered processes and candidate biomarkers for hepatic hemangiosarcoma and its development. *Int J Mol Sci* 2021;22(10):5093.