










A rare case of *Yersinia pseudotuberculosis* liver abscess and bacteremia in a heterozygous carrier of *HFE1 H63D* and *MPEG1* mutations in Türkiye

 Muhammed Alper Ozarslan¹,  Hasan Selcuk Ozkan²,  Mert Pekerbas³,  Bartu Cetin⁴,  Mustafa Mustafayev⁵,
 Fulya Gunsar⁵,  Asude Durmaz³,  Ayca Aykut³,  Sohret Aydemir¹

¹Department of Medical Microbiology, Ege University School of Medicine, Izmir, Türkiye; ²Ege University School of Medicine, Izmir, Türkiye; ³Department of Medical Genetics, Ege University School of Medicine, Izmir, Türkiye; ⁴Department of General Surgery, Ege University School of Medicine, Izmir, Türkiye; ⁵Department of Internal Medicine, Ege University School of Medicine, Izmir, Türkiye

Abstract

Yersinia pseudotuberculosis is a rare pathogenic organism in humans and is encountered mostly in patients with acquired or hereditary iron overload. This case report presents such a case with no known risk factors for iron overload, except heterozygous mutations in *MPEG1* and *HFE* genes, while presenting the first patient with *Y. pseudotuberculosis* liver abscess in Türkiye. Here we present a 63-years-old male with known long-standing hypertension, type 2 diabetes, peripheral artery disease and chronic kidney disease presenting with right upper quadrant pain, nausea, vomiting and fever, whose imaging studies revealed multiple liver abscesses. While investigating the etiology, *Yersinia pseudotuberculosis* growth was observed in his abscess aspiration material and blood culture. Genetic analysis conducted after the detection of a ferritin level of 13725 µg/L, showed a heterozygous *H63D* mutation in *HFE*. Consequent whole-exon-sequencing reported an additional heterozygous p. Thr73Ala mutation in *MPEG1*. Even though, *Y. pseudotuberculosis* is detected mostly in patients with primary hemochromatosis, even heterozygous carriers of hemochromatosis may present clinically if concomitant comorbidities exist and may pose a challenge not only to clinicians but also to laboratory diagnosticians.

Keywords: *HFE* genes, *Yersinia*, *MPEG1*, pseudotuberculosis.

Introduction

Yersinia spp. are zoonotic pathogens belonging to the Yersiniaceae family and encompassing more than 15 pathogens, including *Y. pestis*, *Y. enterocolica* and *Y. pseudotuberculosis*, which are the only human

species in this genus. Swine, rodents and wild birds are known to be the natural reservoirs, as humans serving only as hosts. Most infections occur in humans via fecal-oral route, as drinking contaminated waters or consuming contaminated food, however cases presenting after direct contact with the reservoirs are also known.^[1]

Y. pseudotuberculosis is a fermentative, oxidase-negative, gram-negative facultative anaerobe bacillus, which is motile in room temperature and can strongly ferment rhamnose and melibiose, which serves to distinct it from other human pathogen *Yersinia spp.*^[2] Siderophore-mediated iron uptake and presence of iron in the environment are essential for survival of *Yersinia spp.*, and some strains of *Y. pseudotuberculosis* is known to possess at least three different iron scavenging systems.^[3] The tendency of this pathogen to prefer iron-rich environments, therefore puts some patient groups at higher risk, such as liver cirrhosis, hemochromatosis, venous congestion, and hemolytic anemia, leading in these patients to bacteremia.^[4] Other pathologies associated are acute interstitial nephritis, septic and reactive arthritis, intestinal obstructions and liver abscesses.^[3]

Herewith, we present a male patient of 63 years, with stage 3 chronic kidney disease (CKD), under regular dialysis treatment, who is also carrier of heterozygous *HFE H63D* and *MPEG1* p. Thr73Ala mutations, presenting with laboratory and imaging studies consistent with iron-overload and secondary hemochromatosis.

Case Report

63 years old male patient, with known hypertension (15 years), type 2 diabetes (20 years, treated with insulin), chronic kidney disease (thrice/week dialysis) and peripheral artery disease presented with right epigastric pain, accompanied with nausea, vomiting and fever of 39.5°C. The patient had these symptoms for one week and the first physical examination in the emergency service was compatible with the symptoms, with no signs of peritonitis. First laboratory presented a leukocytosis 17.10×10³/µL and C-reactive protein 228 mg/L. Abdominal computed tomography (CT) conducted in the emergency service was compatible with multiple hypodense lesions in all liver segments, with the largest reaching 26 mms, along with mild thickness of ascending colon and hepatic flexure, reported as possible colitis. An empirical therapy with 2 g of intravenous (IV) ceftriaxone q24h plus 500 mg of IV metronidazole q8h was started and the patient was admitted to intensive care unit.

This case has previously been presented at the 2020 Online Microbiology Symposium of the Turkish Microbiological Society, held in December 25–27, 2020.

How to cite this article: Ozarslan MA, Ozkan HS, Pekerbas M, Cetin B, Mustafayev M, Gunsar F et al. A rare case of *Yersinia pseudotuberculosis* liver abscess and bacteremia in a heterozygous carrier of *HFE1 H63D* and *MPEG1* mutations in Türkiye. *Hepatology Forum* 2024; 5(0):0–0.

Received: July 24, 2023; **Revised:** October 13, 2023; **Accepted:** December 07, 2023; **Available online:** October 25, 2024

Corresponding author: Hasan Selcuk Ozkan; Ege Universitesi Tip Fakultesi, Izmir, Türkiye

Phone: +90 232 390 33 03; **e-mail:** hselcukozkan@gmail.com



OPEN ACCESS
This work is licensed under a Creative Commons Attribution-NonCommercial 4.0 International License.

Hepatology Forum - Available online at www.hepatologyforum.org



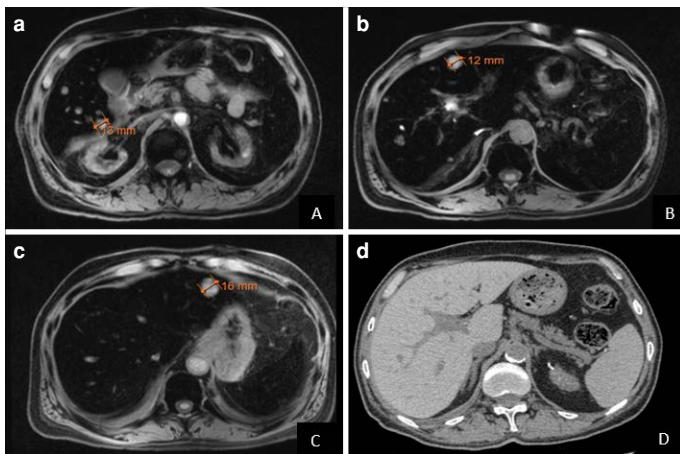


Figure 1. (a–c) Abdominal T2-weighted MRI showing upper abdominal segments with multiple hyperintense lesions of 12–16 mm, and diminished hepatic intensity compatible with iron overload. (d) Follow-up abdominal CT of 5 months later, showing dilated bile ducts with relatively clear parenchyma.

Due to the persistence of fever and inflammatory markers, leukocytosis $20.01 \times 10^3 / \mu\text{L}$ and C-reactive protein (CRP) 234 mg/L, blood cultures were obtained, a magnetic resonance imaging (MRI) was conducted, showing signal diminishment in whole sequences in liver, and an iso-intense spleen, suggestive of metal accumulation (Fig. 1a–c) The abscess material obtained after ultrasound-guided percutaneous needle aspiration was used for microbiological analysis.

Gram-staining of the aspiration material (liver abscess) and blood culture showed small gram-negative coccobacilli. In the direct microscopic examination of the abscess sample, plenty of leukocytes were detected in every field. Blood culture was performed using VersaTREK (Thermo Fisher Scientific, USA) automatized culture system. Abscess sample was cultured on 5% sheep blood agar and eosin methylene blue agar (EMB) (BioMérieux, France). Both agars were cultured separately in aerobic and anaerobic atmosphere. Blood culture bottles with a positive signal were also subcultured to the same agars in an aerobic and anaerobic atmosphere. After 24 hours of incubation in aerobic atmosphere in 36°C incubator, umbonate gray-white colonies in 5% sheep blood agar (Fig. 2) and small needle-tip colonies were observed in EMB agar. These colonies were identified as *Y. pseudotuberculosis* using MALDI-TOF MS (Vitek MS) (BioMérieux, France).

After the detection of *Y. pseudotuberculosis*, the patient's current antibiotic treatment (ceftriaxone and metronidazole) was continued. The automated VITEK-2 system (BioMérieux, France) was used for antibiotic susceptibility testing of the isolates and determined as in Table 1, according to the EUCAST 2020.^[5]

The patient's blood sugar was regulated and he did not need insulin infusion. Although aspartate transaminase (AST) and alanine transaminase (ALT) liver enzymes were not very high (AST: 80 U/L, ALT: 73 U/L), human immunodeficiency virus (HIV) and but acute hepatitis serology (HBsAg, anti-HIV, anti-HCV; Alinity, Abbott Diagnostics, Ireland) were evaluated due to elevated cholestasis parameters (alkaline phosphatase with 1921 U/L and gamma glutamyltransferase with 1454 U/L, total bilirubin: 2.64 mg/dL, direct bilirubin: 2.47 mg/dL). These serological assay results were negative and biliarytract was normal on abdominal ultrasonography evaluation. All cholestasis parameters also showed regression with treatment. After abdominal pain completely dis-

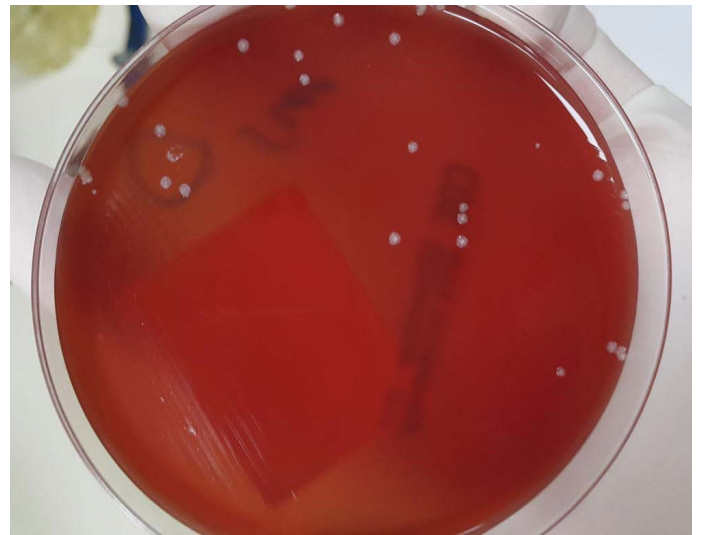


Figure 2. Umbonate gray-white colonies of *Y. pseudotuberculosis* in 5% sheep blood agar.

Table 1. Susceptibility status of the *Y. pseudotuberculosis* isolated from the patient

Antibiotics tested	Susceptibility status
Amoxicillin/clavulanic acid	S (≤ 2.0 mg/ μL)
Ampicillin	S (< 2.0 mg/ μL)
Cefuroxime axetil	S (< 1.0 mg/ μL)
Ceftriaxone	S (< 0.25 mg/ μL)
Cefixime	S (≤ 0.25 mg/ μL)
Amikacin	S (< 2.0 mg/ μL)
Gentamicin	S (< 1.0 mg/ μL)
Ciprofloxacin	S (< 0.25 mg/ μL)

S: Sensitive.

appeared, CRP and leukocytosis regressed, the patient was transferred to the gastroenterology service for etiology investigation and treatment.

Considering that the patient's ferritin level was 13725 $\mu\text{g/L}$, a strip assay was performed in which common mutations in the *HFE* gene were screened for hemochromatosis (ViennaLab diagnostics GmbH, Austria). The strip assay revealed the heterozygous *H63D* mutation, one of the most common pathogenic mutations in the *HFE* gene. Although homozygous or compound heterozygous mutations in the *HFE* gene are responsible for hereditary hemochromatosis, there are also studies indicating that heterozygous *H63D* mutations may also cause elevated serum iron and ferritin levels, albeit rare.^[6,7] Therefore, whole exome sequencing (WES) analysis (Ion S5 Next Generation Sequencing System, Thermo Fisher Scientific™) was planned to investigate other genetic backgrounds that may cause high ferritin levels and hereditary immunodeficiency syndromes that may predispose to atypical *Yersinia pseudotuberculosis* infection. Whole exome sequencing analysis revealed heterozygous c.217A>G mutation in the *MPEG1* gene, although could not detect any other genetic alteration that could explain the high ferritin levels of the patient.

Macrophage-expressed gene 1 (*MPEG1*) encodes a pore-forming protein that is a member of the Membrane Attack Complex/Perforin

(MACPF) protein superfamily and is highly expressed in macrophages and neutrophils.^[8] Pathogenic mutations in the *MPEG1* gene are associated with autosomal dominant Immunodeficiency 77 syndrome (OMIM: #619223), which predisposes to infection with both intracellular and extracellular pathogens. The heterozygous c.217A>G (p. Thr73Ala) (NM_001039396.1) missense variant in the *MPEG1* gene was considered a variant of unknown significance (VUS) according to the American College of Medical Genetics (ACMG) criteria (PM2, PP5, BS2). This variant was also detected by WES in a 70-year-old woman who had a history of pulmonary infections with *Mycobacterium avium* complex (MAC), *Pseudomonas*, *Achromobacter*, and *Aspergillus* species, in a study by McCormack et al.^[9] in 2017. Although the population allele frequencies of the variant were relatively high (0.21% aggregated) in the gnomAD database,^[10] it was thought that this variant may have incomplete penetrance and variable expressivity, and cause late-onset mild immunodeficiency, contributed to the atypical *Y. pseudotuberculosis* infection in the patient.

Additionally, due to chronic irregular diarrhea symptoms and possible colitis image in the abdominal CT, colonoscopy and the cold enrichment method of stool were performed in the 2nd week of the treatment to investigate chronic enteritis and contagiousness. The stool sample was prepared in a tube as a homogenized suspension in 3 cc 0.067 M phosphate buffer solution and kept at 4°C for 3 weeks. The sample on days 0-1-7-14-21 was passaged to EMB agar and incubated at 26°C for 48 hours.^[11] *Y. pseudotuberculosis* did not grow on any agar. Also, nothing additional was observed except one polyp in the colonoscopy. And polyp was a tubular adenoma.

The patient was known to be transfused once because of refractory anemia due to CKD two years ago. During his current treatment, the patient received two erythrocyte suspensions, because his hemoglobin was 6.4 g/dl.

On the 18th day of ceftriaxone and metronidazole treatment, no growth was detected in the peripheral blood culture taken for control. From the patient who was afebrile. In the 4th week of ceftriaxone and metronidazole, an upper abdominal CT was taken for control, the abscess in the liver were similar in size and appearance, and some regression was detected in the multiloculated abscess at the liver segment VI. After 4 weeks, ceftriaxone and metronidazole treatment were changed to IV piperacillin-tazobactam 2.25 g q8h for maintain the decrease in total bilirubin (1.61 mg/dL) and the regression of the liver multiloculated abscess. After 2 weeks of piperacillin-tazobactam treatment, the patient was discharged because his general condition was good, and his vital signs were stable. The patient received a total of 6 weeks of antibiotic therapy. Genetic counseling was given to the family for the mutations found. The follow-up examination of the patient 4.5 months later was normal, fever and pain were not reported during this period. Multiple hypodense lesions in the liver were not observed in the control abdominal CT (Fig. 1d). It was planned to be followed up in the internal medicine outpatient clinic for anemia caused by CKD, keeping iron accumulation under control, and because of his other comorbidities (such as type-2 diabetes and peripheral artery disease).

Discussion

Yersinia pseudotuberculosis, although being a common pathogen in other mammals, is a rare pathogen in humans, presenting with a wide variety of symptoms and underlying conditions. The rarity of this pathogen may subsequently lead to problems not only in clinical

setting but also in laboratory diagnosis, even the most recent MALDI-TOF systems couldn't identify the pathogen correctly, mistaking it as *Y. Pestis*.^[12]

Being an enteric pathogen infecting predominantly the terminal ileum of the small intestine and colonizing the lymphoid tissues there, *Y. pseudotuberculosis* is not known to cause symptoms in healthy individuals, as their intact chemotactic capacity for neutrophils serves to limit bacterial growth, resulting in their early clearance. Long-term persistence of bacteria is known to appear in cecal lymphoid tissues of animal models and in some entomopathogenic nematodes, however no such phenomenon has been shown in humans.^[13]

The main risk group for symptomatic *Y. pseudotuberculosis* infection is the patients with hemochromatosis, which can be either acquired or inherited mainly due to *HFE* gene mutations in autosomal-recessive manner, requiring both alleles being mutated for symptomatic disease.

HFE encodes human homeostatic iron regulator protein, located at 6p22.2, that forms complexes with the transferrin receptor, and its overexpression leads to decreased affinity of transferrin receptor for transferrin and inhibiting the iron efflux from intracellular space. *H63D* mutations of *HFE*, however is not known to interfere with formation of stable complexes and do not increase affinity of transferrin receptor for transferrin. *HFE* protein also raises intracellular iron concentrations by inhibiting iron efflux from monocytes and macrophages, however in patients with *H63D* mutation, mutated *HFE* protein can not inhibit iron release, resulting in the displacement of intracellular iron to the bloodstream.^[14]

As most of the hereditary hemochromatosis is because of C282Y homozygosity,^[15] and to a lesser extent, in most of other cases following mutations including *C282Y/H63D* compound heterozygosity, or *H63D* homozygosity.^[16] Although the heterozygous *H63D* mutation may be associated with high iron and ferritin levels,^[16] it is difficult to say that it is the cause of the symptoms due to iron-excess in the patient. On the other hand, the heterozygous p. Thr73Ala mutation in the *MPEG1* gene may have caused late-onset immunodeficiency and predisposed to the patient's *Yersinia* infection.

Nonetheless, in the case presented, the patient, who was heterozygous for *H63D* mutation in *HFE* and p. Thr73Ala mutation in *MPEG1*, could be immunocompromised, showed clinical symptoms of iron-overload, eventually predisposing him for bacteremia and liver abscesses with *Y. pseudotuberculosis*, a bacterium requiring iron to thrive. The case presented is of utmost interest with all these clinical findings. Patients with similar clinical conditions may need long-term treatment as in our case. According to the literature review, the patient is the first case of *Y. pseudotuberculosis* liver abscess in Turkey.

Author Contributions: Concept – SA, MAO, HSO, MP; Design – MP, MAO, AA, AD; Supervision – SA, FG, AA, AD; Materials – BC, MP, MAO, MM; Data Collection and/or Processing – MAO, HSO, SA, MP; Analysis and/or Interpretation – MAO, HSO, SA, MP; Literature Search – MAO, HSO, MP, AA, AD; Writing – MAO, HSO, SA, MP; Critical Reviews – MP, HSO, MAO.

Conflict of Interest: The authors have no conflict of interest to declare.

Informed Consent: Written informed consent was obtained from the patient for the publication of the case report and the accompanying images.

Use of AI for Writing Assistance: Not declared.

Financial Disclosure: The authors declared that this study has received no financial support.

Peer-review: Externally peer-reviewed.

References

1. Prentice MB, Rahalison L. Plague. *Lancet* (London, England) 2007;369(9568):1196-1207.
2. Koneman EW, Allen S. Koneman. *Diagnostico Microbiologico/Microbiological diagnosis: Texto Y Atlas En Color/Text and Color Atlas*. Ed. médica panamericana; 2008. p. 279–285.
3. Rakin A, Schneider L, Podladchikova O. Hunger for iron: the alternative siderophore iron scavenging systems in highly virulent *Yersinia*. *Front Cell Infect Microbiol* 2012;2:151.
4. Stanger KJ, McGregor H, Larsen J. Outbreaks of diarrhoea ('winter scours') in weaned Merino sheep in south-eastern Australia. *Aust Vet J*. 2018;96(5):176-183.
5. The European Committee on Antimicrobial Susceptibility Testing. Breakpoint tables for interpretation of MICs and zone diameters. Version 9.0 [Internet]. 2019. Available from: <http://www.eucast.org>
6. Njajou OT, Houwing-Duistermaat JJ, Osborne RH, Vaessen N, Vergeer J, Heeringa J, et al. A population-based study of the effect of the HFE C282Y and H63D mutations on iron metabolism. *Eur J Hum Genet* 2003;11(3):225-231.
7. Gochee PA, Powell LW, Cullen DJ, Du Sart D, Rossi E, Olynyk JK. A population-based study of the biochemical and clinical expression of the H63D hemochromatosis mutation. *Gastroenterology* 2002;122(3):646-651.
8. Bayly-Jones C, Pang SS, Spicer BA, Whisstock JC, Dunstone MA. Ancient but Not Forgotten: New Insights Into MPEG1, a Macrophage Perforin-Like Immune Effector. *Front Immunol* 2020;11:581906.
9. McCormack RM, Szymanski EP, Hsu AP, Perez E, Olivier KN, Fisher E, et al. MPEG1/perforin-2 mutations in human pulmonary nontuberculous mycobacterial infections. *JCI Insight* 2017;2(8):e89635.
10. MPEG1 | gnomAD v2.1.1 | gnomAD. Accessed on 2023 Feb 22. Available at: https://gnomad.broadinstitute.org/gene/ENSG00000197629?dataset=gnomad_r2_1
11. Oberhofer TR, Podgore JK. *Yersinia pseudotuberculosis*: use of cold-temperature enrichment for isolation. *J Clin Microbiol* 1980;11(1):106-108.
12. Sim EM, Koh B, Ng J, Nguyen T, Wang Q, Ginn AN, et al. Case report: a genomics-guided reclassification of a blood culture isolate misassigned by MALDI-TOF as *Yersinia pestis*. Vol. 4, *Access microbiology*. England; 2022. p. acmi000422.
13. Gengler S, Laudisoit A, Batoko H, Wattiau P. Long-term persistence of *Yersinia pseudotuberculosis* in entomopathogenic nematodes. *PLoS One* 2015;10(1):e0116818.
14. Drakesmith H, Sweetland E, Schimanski L, Edwards J, Cowley D, Ashraf M, et al. The hemochromatosis protein HFE inhibits iron export from macrophages. *Proc Natl Acad Sci U S A* 2022;99(24):15602-15607.
15. Atkins JL, Pilling LC, Masoli JAH, Kuo CL, Shearman JD, Adams PC, et al. Association of hemochromatosis HFE p.C282Y homozygosity with hepatic malignancy. *JAMA* 2020;324(20):2048-2057.
16. Gurrin LC, Bertalli NA, Dalton GW, Osborne NJ, Constantine CC, McLaren CE, et al. HFE C282Y/H63D compound heterozygotes are at low risk of hemochromatosis-related morbidity. *Hepatology* 2009;50(1):94-101.