









# Action of melatonin and physical exercise on the liver of cirrhotic rats: Study of oxidative stress and the inflammatory process

 Gabriela S Martins<sup>1,2</sup>,  Carlos Gustavo S Rosa<sup>3</sup>,  Elizangela G Schemitt<sup>2</sup>,  Josieli R Colares<sup>2</sup>,  Sandielly RB Fonseca<sup>2</sup>,  
 Marilda S Brasil<sup>1,2</sup>,  Millena O Engeroff<sup>2</sup>,  Norma P Marroni<sup>1,2</sup>

<sup>1</sup>Department of Physiology, Faculty of Biological Sciences, Federal University of Rio Grande do Sul (UFRGS), Porto Alegre, Rio Grande do Sul, Brazil; <sup>2</sup>Experimental Laboratory of Pulmonology and Inflammation Sciences - Experimental Research Center, Hospital de Clínicas de Porto Alegre (HCPA), Porto Alegre-RS, Brazil; <sup>3</sup>Cellular and Molecular Biology Program, Lutheran University of Brazil (ULBRA), Canoas-RS, Brazil

## Abstract

**Background and Aim:** Cirrhosis is characterized by structural and functional alterations of the liver. Melatonin (MLT) has antioxidant properties. Physical exercise (EX) can reverse muscle loss in cirrhotic patients. The objective was to evaluate the action of MLT and EX on the liver of rats subjected to the experimental model of bile duct ligation (BDL).

**Materials and Methods:** 48 male Wistar rats were used, divided into groups: Control (CO), CO+MLT, CO+EX, CO+MLT+EX, BDL, BDL+MLT, BDL+EX, and BDL+MLT+EX. The treatments occurred from the 15<sup>th</sup> to the 28<sup>th</sup> day. The dose of MLT was 20 mg/kg via I.p (1x/day), and the EX was performed 10 min/day. Blood and liver were collected for analysis.

**Results:** The liver integrity enzymes AST, ALT, and ALP showed a significant reduction in the groups treated with MLT and EX. Histological analyses showed reorganization of the liver parenchyma, reduction of inflammatory infiltrate, and fibrotic nodules. Lipoperoxidation (LPO), the activity of antioxidant enzymes, and nitric oxide metabolites showed a significant reduction in the groups treated with MLT and EX. The expression of TNF- $\alpha$  and NF- $\kappa$ B decreased in the treated groups.

**Conclusion:** Melatonin and physical exercise seem to be effective in restoring the parameters evaluated in this model of experimental cirrhosis.

**Keywords:** Cirrhosis; melatonin; physical exercise.

## Introduction

Diseases affecting the liver are known to represent one of the greatest public health problems. In this context, it is known that liver cirrhosis is among the most common diseases and is cited for its high mortality rates.<sup>[1-3]</sup> Cirrhosis is a chronic liver disease characterized by the presence of fibrosis and diffuse nodular formation, with consequent disorganization of the lobular and vascular architecture of the organ, leading to changes in liver functions.<sup>[3,4]</sup>

Oxidative stress (OS) plays a central role in the pathogenesis and progression of chronic diseases such as cirrhosis. Antioxidants have been used in the treatment of systemic and liver damage caused by the disease. Increased activation of reactive oxygen species (ROS) generating enzymes, pro-inflammatory cytokines, and vasodilators are associated with the pathophysiology of cirrhosis and the common bile duct ligation (BDL) model.<sup>[5]</sup>

For the induction of secondary biliary cirrhosis and fibrosis, prolonged obstruction of the bile duct in rats has proven to be an effective experimental model since the characteristics of the disease in this model are established in a period of 28 days. During this period, the obstruction causes dilation of the bile duct, edema, and acute inflammatory reactions due to bile reflux and the appearance of periportal fibrosis due to alterations in the synthesis and degradation of proteins such as collagen, causing disorganization of the hepatic parenchyma.<sup>[6-8]</sup>

Patients with livers affected by cirrhosis may have abnormal nutrient metabolism, altered digestion and absorption, along with increased protein catabolism and increased protein-energy requirements. This nutritional deficiency can lead to a decrease in skeletal muscle mass, leading to sarcopenia.<sup>[9]</sup>

Physical exercise seems to be a useful therapy for improving functional capacity in individuals with liver disease, but it is not clear whether exercise can restore liver health or what amount and type of exercise is needed. Physical activity may have some direct positive influence on liver pathology besides the simple modification of liver fat levels, and it appears that the intensity of physical activity is important to prevent disease progression.<sup>[10]</sup>

Melatonin (MLT), N-acetyl-5-methoxytryptamine, has been widely studied and cited in different studies as a potent antioxidant (AOX), acting in the reduction of free radicals (hydroxyl and peroxy).<sup>[11,12]</sup> Studies indicate that the combination of supplementation with antiox-

**How to cite this article:** Martins GS, Gustavo CSR, Schemitt EG, Colares JR, Fonseca SR, Brasil MS, et al. Action of melatonin and physical exercise on the liver of cirrhotic rats: Study of oxidative stress and the inflammatory process. *Hepatology Forum* 2024; 5(4):184–192.

**Received:** December 18, 2023; **Revised:** February 22, 2024; **Accepted:** April 04, 2024; **Available online:** September 00, 2024

**Corresponding author:** Norma P Marroni; Department of Physiology, Faculty of Biological Sciences, Federal University of Rio Grande do Sul (UFRGS), Porto Alegre, Rio Grande do Sul, Brazil

**Phone:** +55 51 99212-2637; **e-mail:** nmarroni@terra.com.br



OPEN ACCESS  
This work is licensed under a Creative Commons Attribution-NonCommercial 4.0 International License.

*Hepatology Forum* - Available online at [www.hepatologyforum.org](http://www.hepatologyforum.org)



ident properties and physical exercise plays an important role in the modulation of some physiological parameters.<sup>[13]</sup> Thus, this work seeks to investigate liver changes resulting from cirrhosis as well as the possible intervention of an antioxidant treatment with MLT and physical exercise in this disease.

## Materials and Methods

### Ethical Aspects

The research project was approved by the Federal University of Rio Grande do Sul Ethics Committee on Animal. All procedures were performed in accordance with Federal Law No. 11.794 of October 8, 2008, which regulates the use of animals in scientific research. The analysis was carried out using blood and liver tissue samples already collected and properly stored.

### Experimental Model

Forty-eight male Wistar rats weighing between 200 and 300 grams were used. The animals were submitted to the experimental model of bile duct ligation (BDL) for the induction of secondary biliary cirrhosis. For the study, the animals were divided into 8 experimental groups with 6 animals in each group: Control (CO), control + melatonin (CO+MLT), control + physical exercise (CO+EX), control + melatonin + physical exercise (CO+MLT+EX), bile duct ligation (BDL), bile duct ligation + melatonin (BDL+MLT), bile duct ligation + exercise (BDL+EX), bile duct ligation + melatonin + exercise (BDL+MLT+EX). During the experiment, the animals were kept in plastic boxes measuring 47x34x18 cm, lined with shavings, on a twelve-hour light/dark cycle at a temperature of 22±2 °C. Water and food were given freely.

The animals were weighed and anesthetized by administering anesthetic drugs (Xylazine and Ketamine) I.p. Then, they underwent trichotomy, disinfection of the abdominal region, and laparotomy to locate and dissect the bile duct at the level of the mouth of the pancreatic ducts, connecting these by means of two knots (using 3-0 silk thread) and posteriorly sectioning between them. The suture of the muscle tissue was performed with continuous stitches, with 4.0 absorbable polyglactin thread. The skin was sutured with isolated stitches using 5.0 non-absorbable monofilament nylon thread.<sup>[5,6]</sup> The animals in the CO, CO+MLT, CO+EX, and CO+MLT+EX groups were not submitted to BDL; only the manipulation of the duct through surgical stress was performed.

### Physical Exercise

Physical exercise started on the 15<sup>th</sup> day after the BDL surgical procedure or control simulation, daily, until the 28<sup>th</sup> day. The animals were placed to swim in pairs, in a box measuring 60 x 40 cm and 50 cm deep, maintaining the temperature between 28-32 °C, controlled with a thermometer, and kept there for 10 minutes, every day.<sup>[14,15]</sup> The animals in the CO, CO+MLT, BDL, and BDL+MLT groups performed only one simulation of physical activity with the rats placed in a tank with water only 5 cm deep at the same temperature of 28-32 °C for 5 minutes.

### Administration of Melatonin and Vehicle

Treatments with MLT started on the 15<sup>th</sup> day after BDL, daily for 14 days. The animals in the CO and BDL groups received saline solution (0.9% NaCl) at a dose of 0.5 mL, while the animals in the CO+MLT

and BDL+MLT groups received melatonin, which was weighed and prepared daily, always under light protection, at a dose of 20 mg/kg of body weight being diluted, using a mixture of 5 µL of 1% ethanol and 0.5 mL of 0.9% NaCl.<sup>[16]</sup>

## Analyzes

### Assessment of Liver Integrity

Serum levels of alanine aminotransferase (ALT) and aspartate aminotransferase (AST) were determined by the ultraviolet kinetic test. Alkaline phosphatase (ALP) was quantified by the kinetic colorimetric test through an automated enzymatic method (Siemens Advia 1800 Chemistry system).

### Histological Analysis

For histological evaluation, after anatomical dissection of the liver of each animal, approximately 2 cm of tissue was removed and placed in 10% formaldehyde for fixation for 24 hours, followed by histological processing (dehydration in a graduated series of six concentrations of alcohol, compensating with xylene in two concentrations, and embedding in paraffin at 64 °C). The paraffin blocks were cut with a rotating microtome at a thickness of 6 µm. Subsequently, Hematoxylin-Eosin and picosirius staining techniques were performed, showing damage to the liver tissue. The slides were analyzed under a binocular microscope Nikon Labophot at different magnifications at the Pathology Service.

### Preparation of Homogenate and Protein Dosage

Phosphate buffer solution (KCl 1.15%) and phenyl methyl sulfonyl fluoride (PMSF) were used at a concentration of 100 mM in isopropanol. The tissue was homogenized in ULTRA-TURRAX and centrifuged in a refrigerated centrifuge. The supernatant was used for further biochemical analysis.<sup>[17]</sup> The protein concentration in the homogenates was determined using the Bradford method (1976).

### Assessment of Lipoperoxidation

The lipoperoxidation was determined using the technique of substances that react to thiobarbituric acid (TBARS).<sup>[18]</sup> The amount of aldehydes generated by lipid peroxidation (LPO) was determined by a method that measures the amount of thiobarbituric acid reactivity. Thiobarbituric acid (TBA) was added to the samples at 0.37%, while trichloroacetic acid (TCA) was added at 15%, used to denature the proteins present and acidify the reaction. Samples were incubated at 100 °C for 15 minutes and then cooled on ice for approximately 5 minutes. After cooling the samples, 1.5 mL of n-butyl alcohol was added to extract the pigment formed. Samples were shaken for 45 seconds and centrifuged at 3,000 rpm (1,612 x g) for 10 minutes at 4 °C. Absorbance was determined by spectrophotometry at 535 nm. The concentration of TBARS obtained was expressed as nmol/mg of protein.<sup>[19]</sup>

### Activity of the Antioxidant Enzyme Superoxide Dismutase (SOD)

The enzymatic activity of SOD was measured by evaluating the ability of the enzyme to inhibit the reaction of the superoxide radical with adrenaline. Reading was performed at 480 nm. Data are expressed in Units USOD/min/mg prot.<sup>[20]</sup>

**Table 1.** Evaluation of liver integrity enzymes

Group	AST (U/L)	ALT (U/L)	ALP (U/L)
CO	86.93±1.55	38.44±1.41	126.42±10.81
CO+MLT	93.51±10.38	37.92±1.73	118.16±8.50
CO+EX	78.38±3.68	37.53±1.72	125.32±10.18
CO+MLT+EX	93.36±8.77	36.75±1.63	138.62±9.70
BDL	305.265±24.99*	83.96±9.70*	406.63±37.36*
BDL+MLT	115.3±20.58#	41.85±5.00#	107.98±8.66#
BDL+EX	90.56±10.33#	43.58± 3.80#	153.80±11.30#
BDL+MLT+EX	118.42±17.23#	49.85±4.53#	138.52±18.26#

AST: Aspartate aminotransferase; ALT: Alanine aminotransferase; CO: Control; CO+ML: Control+melatonin; CO+MLT+EX: Control+melatonin+physical exercise; BDL: Bile duct ligation; BDL+EX: Bile duct ligation+exercise; BDL+MLT: Bile duct ligation+melatonin; BDL+EX: Bile duct ligation+physical exercise; BDL+MLT+EX: Bile duct ligation+melatonin+physical exercise. Data are expressed as mean±standard error. \*: Significant increase in the LDB group compared to controls (p<0.05); #: Significant decrease in the BDL+MLT, BDL+EX and BDL+MLT+EX groups compared to the BDL group (p<0.05).

**Activity of the Antioxidant Enzyme Catalase (CAT)**

Catalase activity (CAT) was determined by measuring the decrease in absorption in action medium containing 50 mmol/L of phosphate-buffered saline (pH 7.2) and 0.3 mol/L of hydrogen peroxide. Enzymatic activity was analyzed spectrophotometrically at 240 nm and expressed as pmol/mg of protein.<sup>[21]</sup>

**Activity of Glutathione Peroxidase (GPx)**

The activity of the antioxidant enzyme GPx was evaluated by the oxidation rate of NADPH in the presence of reduced glutathione and glutathione reductase. The measurement was performed in a spectrophotometer at 340 nm, and its activity was expressed in mmol/min/mg prot.<sup>[22]</sup>

**Evaluation of Nitric Oxide Metabolites**

Nitric oxide production was measured indirectly through a quantitative colorimetric test based on the enzymatic reduction of nitrites to nitrites. The reading was performed at 540 nm and the results expressed in mmol of NO<sub>2</sub>/NO<sub>3</sub>.<sup>[23]</sup>

**Table 2.** Assessment of oxidative stress

Group	TBARS nMol/mg prot	SOD USOD/mg prot	CAT pmoles/min/mg prot	GPx nmoles/min/mg prot
CO	0.179±0.022	1.589±0.337	2.81±0.06	4.803±0.526
CO+MLT	0.193±0.029	1.529±0.220	2.79±0.30	5.314±0.294
CO+EX	0.185±0.045	1.188±0.193	4.27±0.44	5.554±0.297
CO+MLT+EX	0.159±0.022	2.398±0.325	5.16±0.44	6.253±0.099
BDL	0.512±0.085*	10.343±1.423*	10.96±1.37*	10.738±1.345*
BDL+MLT	0.236±0.050##	2.144±0.736#	6.66±0.43##	4.970±0.397#
BDL+EX	0.318±0.092#	1.836±0.755#	8.37±0.55#	5.755±1.029#
BDL+MLT+EX	0.185±0.036##	0.931±0.245#	3.00±0.44##	7.221±1.034#

TBARS: Thiobarbituric acid; SOD: Superoxide dismutase; USOD: Units superoxide dismutase; CAT: Catalase activity; GPx: Glutathione peroxidase; CO: Control; CO+ML: Control+melatonin; CO+MLT+EX: Control+melatonin+physical exercise; BDL: Bile duct ligation; BDL+EX: Bile duct ligation+exercise; BDL+MLT: Bile duct ligation+melatonin; BDL+EX: Bile duct ligation+physical exercise, BDL+MLT+EX: Bile duct ligation+melatonin+physical exercise. Data are expressed as mean±standard error. \*: Significant increase in the LDB group compared to controls; \*: P<0.001; #: P<0.01; ##: P<0.05.

**Immunohistochemical Evaluation**

Liver tissue samples were fixed in 10% formaldehyde and placed in a histological tissue processor (ANCAP), through a graded series of ethanol and two xylene vats for dehydration and rehydrated with different ethanolic grades. The specimens were then embedded and the blocks were cooled, shaped, and connected to a microtome (Leitz® 1512) to obtain 4 µm thick slices. They were incubated with antibodies (TNF-α and NF-kB) (Santa Cruz Biotechnology®). The results were evaluated by a pathologist, through a microscope equipped with a digital camera for image capture (NIKON LABOPHO), binocular microscope with 200× magnification. The level was determined by multiplying the average density of the image by the percentage of the area positively stained by the antibodies (areas of brown color obtained by the peroxidase + diaminobenzidine reaction).

**Statistical Analysis**

Data were presented as mean and standard error of mean and calculated using the GraphPad InStat software, version 3.0 for Windows®. Analysis of variance (ANOVA) was performed followed by the Student-Newman-Keuls test, with a significance level of 5% (p<0.05).

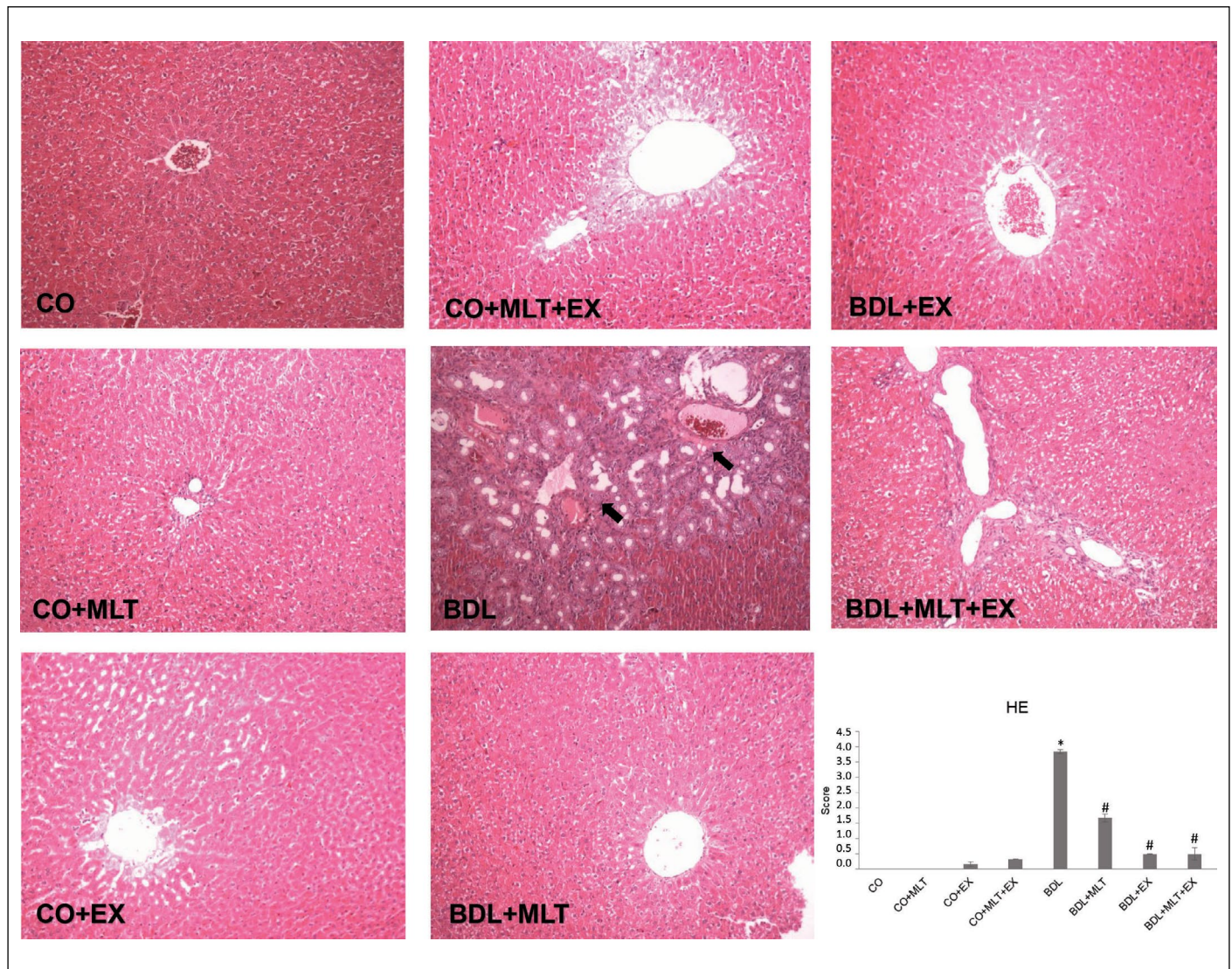
**Results**

**Liver Integrity Enzymes AST, ALT, and ALP**

In the assessment of liver integrity enzymes performed in plasma, it was observed a significant increase in the evaluated markers (AST, ALT, and ALP) in the BDL group compared with the control groups (CO, CO+MLT, CO+EX, and CO+MLT+EX), as well as a significant decrease in these values when MLT was administered and physical exercise was performed in the BDL+MLT, BDL+EX, and BDL+MLT+EX groups compared to the BDL group (Table 1, p≤0.01).

**Histological Evaluation by Hematoxylin and Eosin (HE)**

In the control groups (CO, CO+MLT, CO+EX, CO+MLT+EX), the histological analysis of the liver tissue by HE staining revealed normal liver parenchyma with clearly defined cords of hepatocytes. In the BDL group, there was tissue disorganization with loss of hepatocyte cords and inflammatory infiltrate. In the cirrhotic groups that received treatment with melatonin and/or exercises (BDL+MLT, BDL+EX, BDL+MLT+EX), it was observed a restructuring of these patterns with the formation of hepatocyte cords from the centrilobular vein (Fig. 1).



**Figure 1.** Histology of the liver by HE.

200x magnification in the different experimental groups. The black arrows indicate the presence of an inflammatory infiltrate. Data are expressed as mean±standard error. \*:  $P < 0.001$ ; #:  $P < 0.001$ ; CO: Control; CO+MLT: Control+melatonin; CO+MLT+EX: Control+melatonin+exercise; BDL: Bile duct ligation; BDL+MLT: Bile duct ligation+melatonin; BDL+EX: Bile duct ligation+exercise; BDL+MLT+EX: Bile duct ligation+melatonin+exercise.

### Picrosirius

Evaluation of liver fibrosis in sections stained with Picrosirius revealed the absence of fibrotic septa in the control groups (CO, CO+MLT, CO+EX, and CO+MLT+EX). In animals submitted to BDL, there was a positive marking compatible with the presence of fibrotic septa. However, in groups that received treatment (BDL+MLT, BDL+EX, and BDL+MLT+EX), fibrosis was minimal or non-existent (Fig. 2).

### Oxidative Stress

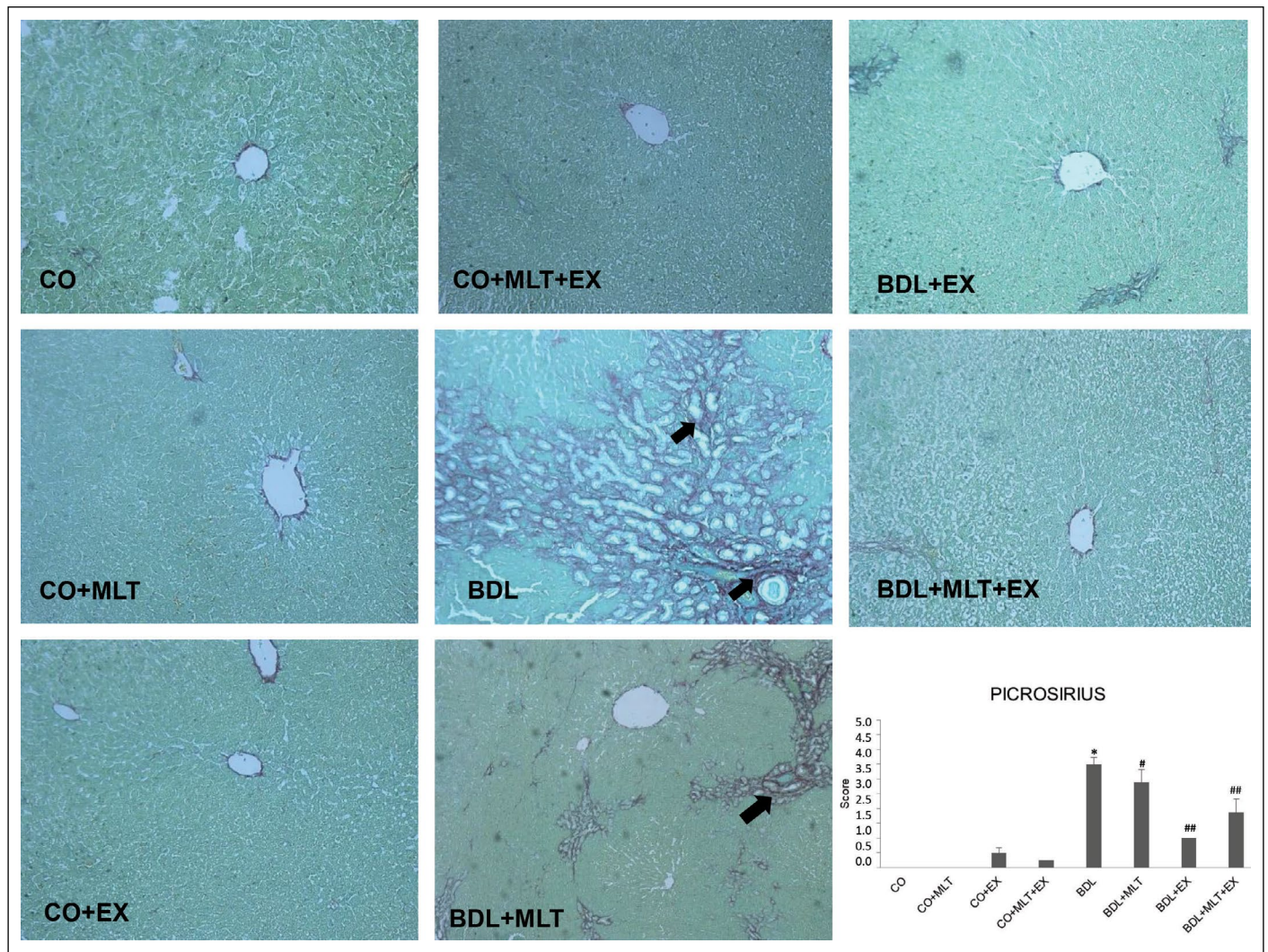
When evaluating LPO, it was observed that TBARS levels showed a significant increase in the BDL group when compared to the CO, CO+MLT, CO+EX, and CO+MLT+EX groups. The groups treated with melatonin and/or physical exercise (BDL+MLT, BDL+EX, and BDL+MLT+EX) showed a significant reduction when compared to the BDL group (Table 2).

### Nitric Oxide Metabolites (Nitrites and Nitrates)

The levels of nitric oxide metabolites  $\text{NO}_2/\text{NO}_3$  showed a significant increase in the BDL group when compared to the CO, CO+MLT, CO+EX, and CO+MLT+EX groups ( $p \leq 0.001$ ). The groups treated with melatonin and/or physical exercise (BDL+MLT, BDL+EX, and BDL+MLT+EX) showed a significant reduction when compared to the BDL group ( $p \leq 0.001$ ) (Fig. 3).

### Expression of Tumor Necrosis Factor Alpha (TNF- $\alpha$ ) by Immunohistochemistry

The liver samples from the BDL group showed strong positive staining for TNF- $\alpha$ , while specimens from the CO, CO+MLT, CO+EX, and CO+MLT+EX groups did not show strong staining. Melatonin treatment and exercise significantly reduced TNF- $\alpha$  expression in the BDL+MLT, BDL+EX, and BDL+EX+MLT groups compared to the BDL group ( $p < 0.001$ ) (Fig. 4).



**Figure 2.** Picrosirius liver histology.

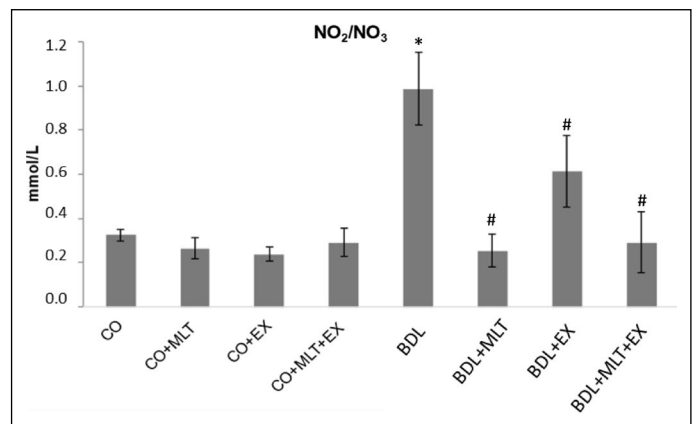
200x increase. The black arrows represent the fibrotic septa. Data are expressed as mean±standard error. \*: P<0.001; #: P<0.05; ##: P<0.001.

### Expression of Nuclear Factor Kappa B (NF-κB)

To assess the inflammatory process, NF-κB levels were measured. The animals in the BDL group had a significant increase in NF-κB levels, observed by the marked staining in the group when compared to the animals in the control groups. When treated with MLT/EX, it was observed a significant decrease in the expression of this protein when compared to the BDL group (p<0.001) (Fig. 5).

### DISCUSSION

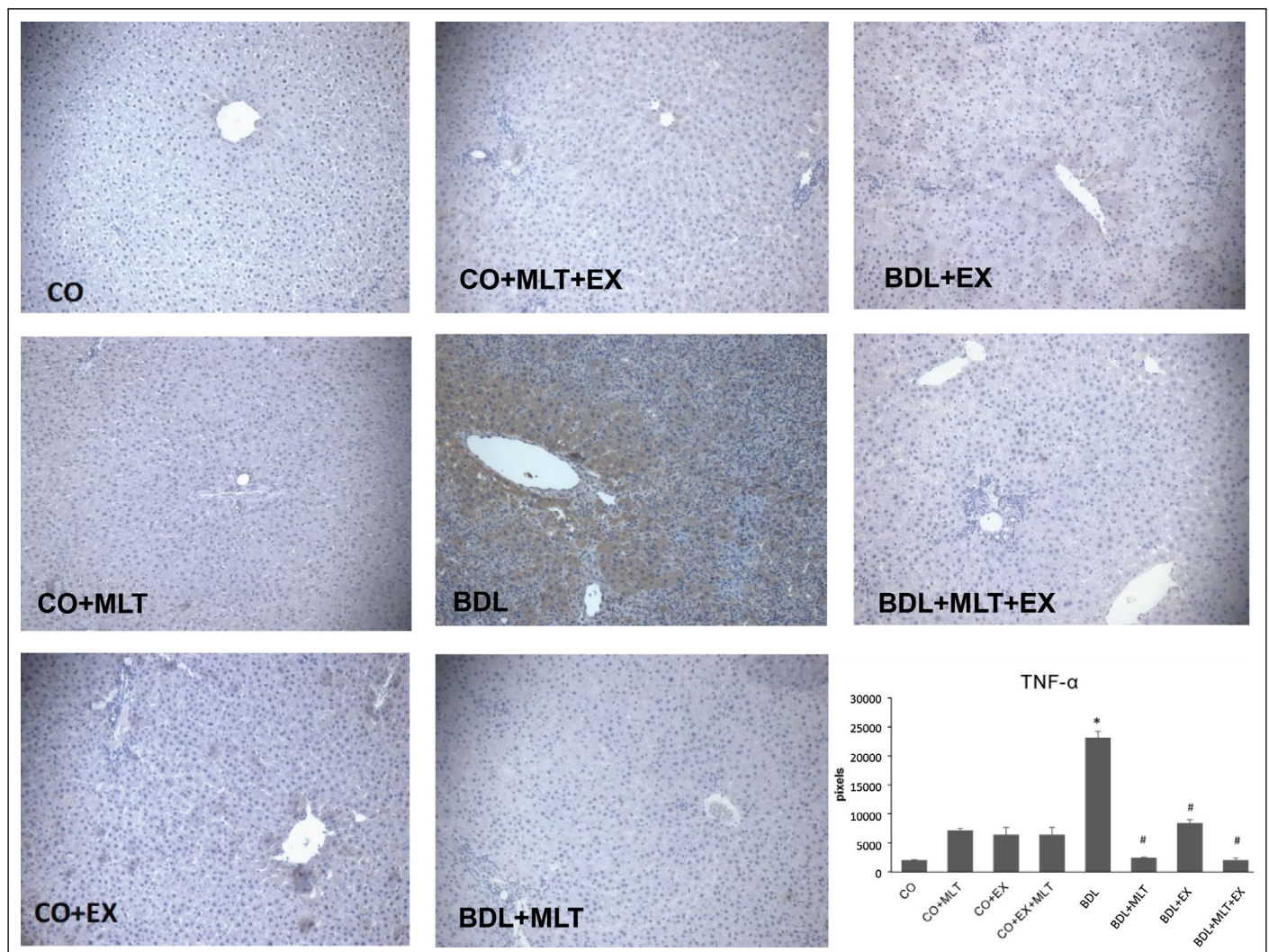
Characterized by the rupture of the liver parenchyma, cirrhosis is the most advanced stage of fibrosis, as a healing response of the liver, which can be inflammatory, toxic, metabolic, or congestive in nature.<sup>[4]</sup> The animal model of bile duct ligation (BDL) established by Kountouras et al.<sup>[6]</sup> and adapted by Fernandes and Mies,<sup>[24]</sup> aiming at obtaining similar alterations of cirrhosis, is widely used due to its reproducibility and ability to resemble the disease in humans. Hepatic structural alterations can be observed from the 15<sup>th</sup> day of BDL surgery, as evidenced by several authors.<sup>[5,7,25–27]</sup>



**Figure 3.** Evaluation of nitrites and nitrates.

Data are expressed as mean±standard error. \*: P≤0.001; #: P≤0.001.

Due to its antioxidant action, MLT reduces oxidative damage by modulating the number of antioxidant enzymes,<sup>[28]</sup> with no reports



**Figure 4.** TNF- $\alpha$  expression.

200x magnification in the different experimental groups. Data are expressed as mean $\pm$ standard error. \*:  $P \leq 0.001$ ; #:  $P \leq 0.001$ .

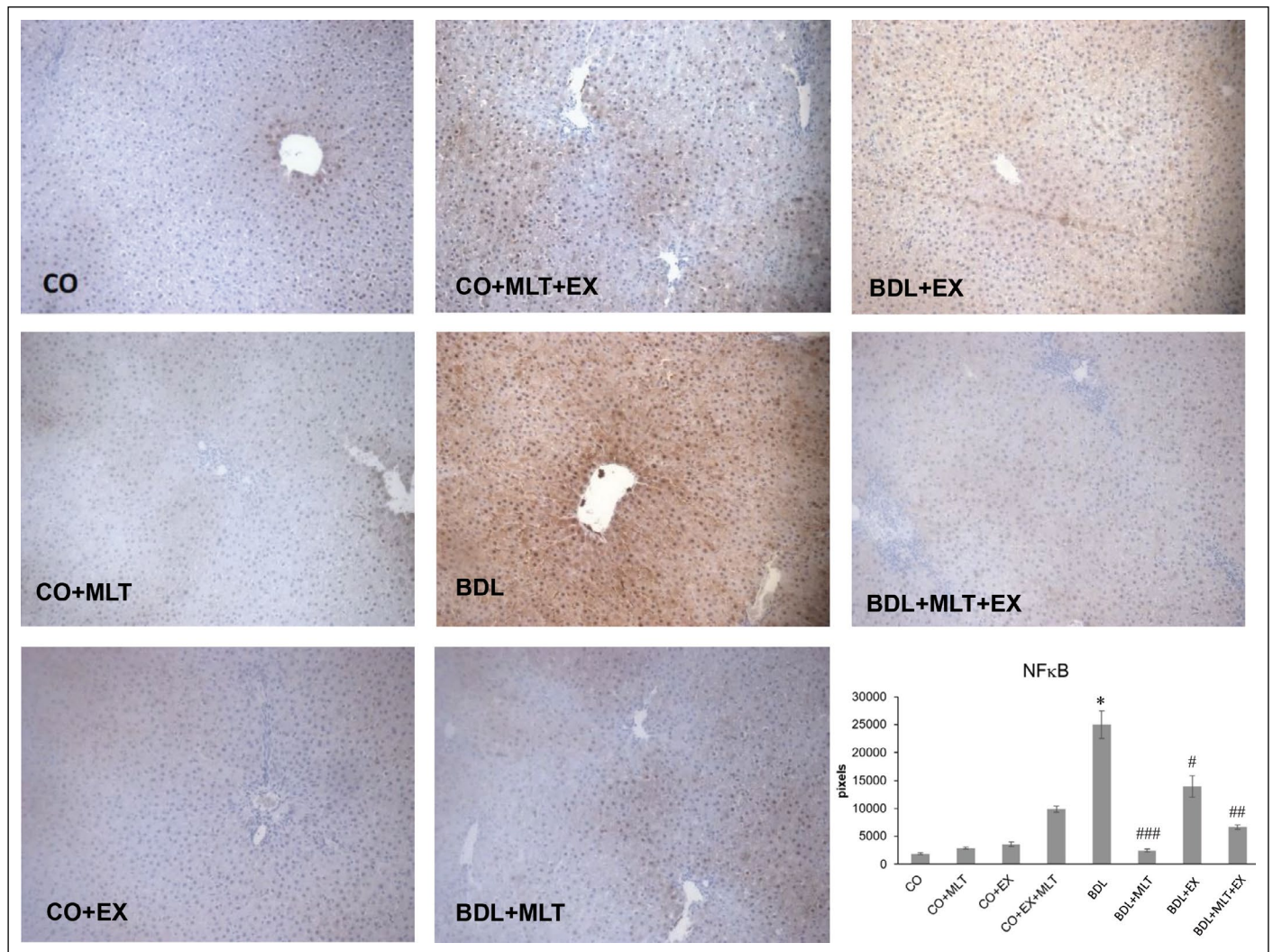
of serious toxicity after its use.<sup>[8]</sup> MLT protects the liver and other tissues, acting against free radicals.<sup>[12]</sup>

The progression of cirrhosis increases the risk of malnutrition and loss of muscle mass.<sup>[29,30]</sup> Physical exercise can be compared to drug prescription in cases of metabolic pathologies, as it promotes several molecular and cellular changes in various tissues, sustaining profuse homeostatic actions. These same changes can occur in cirrhosis. Seeking to reduce the damage of liver cirrhosis, melatonin and physical exercise (swimming) were used as a treatment in animals with BDL.<sup>[15]</sup>

When evaluating liver integrity enzymes AST, ALT, and ALP, it was observed a significant increase in the BDL group, which can occur from damage to the membranes of hepatocytes, with changes in their permeability, and/or acute cell injury with enzymatic extravasation.<sup>[31,32]</sup> The results of this pathogenic study showed that the administration of MLT significantly reduced the activity of enzymes related to liver integrity. These results corroborate the findings of Bona et al.<sup>[33]</sup> using the carbon tetrachloride (CCl<sub>4</sub>) model for cirrhosis induction, in which the animals demonstrated a significant increase in AST, ALT, and ALP levels and equally marked reductions after treatment with the antioxi-

dant quercetin. The study by Colares et al.<sup>[8]</sup> showed the effectiveness of the BDL model for inducing cirrhosis; the treatment performed with antioxidant melatonin managed to significantly reduce the increase in the activity of liver integrity enzymes increased by the disease.

In the liver histology evaluated by HE staining, the groups that underwent the BDL showed disorganization of the cell parenchyma with loss of hepatocyte cords and the presence of an inflammatory infiltrate. The BDL+MLT and BDL+MLT+EX groups showed a decrease in the inflammatory infiltrate, as well as a reorganization of the hepatic parenchyma similar to that of the control groups. These findings are similar to those of Tieppo et al.<sup>[26]</sup> where animals with BDL had liver changes with ductular proliferation and fibrosis, which improved when treated with quercetin. Rosa et al.<sup>[15]</sup> used a swimming protocol with rats lasting 10 minutes in activity and observed positive results in the restoration of the hepatic parenchyma, findings that corroborate this research. In rats with NASH, a treadmill running regimen reduced markers of fibrosis.<sup>[34]</sup> We can infer from these tests that physical exercise has a beneficial effect on hepatocellular damage and on the inflammatory processes resulting from cirrhosis, as well as the use of MLT decreased the presence of inflammatory infiltrate and reduced oxidative damage.<sup>[28]</sup>



**Figure 5.** NF- $\kappa$ B expression.

200X magnification in the different experimental groups. Data are expressed as mean  $\pm$  standard error. \*:  $P < 0.001$ ; #:  $P < 0.01$ ; ###:  $P < 0.001$ .

Picrosirius staining revealed increased collagen deposition, ductular proliferation, and fibrotic septa forming hepatic nodules in animals in the BDL group, and when treated with melatonin, liver changes improved.<sup>[5]</sup> The use of MLT and physical exercise, alone or in combination, caused a reduction in fibrosis markers. Studies have shown that exercise has a direct effect on lipid flow, contributing to the reduction of liver fat.<sup>[35]</sup>

In this study, LPO levels were higher in the BDL group and significantly reduced in the treated groups (BDL+MLT, BDL+EX, and BDL+MLT+EX), suggesting that the treatments demonstrated a therapeutic effect on biological membranes. MLT was able to reduce lipoperoxidation in this model, corroborating other studies.<sup>[32,36]</sup> Physical exercise proved to be effective in reducing LPO in the liver of cirrhotic rats, similar results found in the evaluation of LPO in the quadriceps muscle of rats with sarcopenia induced by cirrhosis, with physical exercise promising in improving LPO in the muscle of these animals.<sup>[15]</sup> Unlike MLT, which is shown in several studies as a potent antioxidant capable of reducing hepatic LPO, more studies must be carried out in order to prove the effectiveness of exercise to reduce LPO in the liver of cirrhotic rats.

In the analysis of the antioxidant enzymes SOD, CAT, and GPx, there was a significant increase in the BDL group when compared to controls, and their activity was reduced in the groups treated with MLT and EX, demonstrating the anti-inflammatory effect of MLT, and a more effective effect when associated with physical exercise. The increases observed in cirrhotic animals may be associated with enzymatic activation in an attempt to minimize oxidative damage resulting from the disease.<sup>[37]</sup>

Exhaustive exercise generates free radicals. This can be evidenced by increased lipid peroxidation and oxidative damage to proteins.<sup>[38,39]</sup> In a review study, the authors found that the regular practice of non-exhaustive aerobic physical exercise, that is, one that does not cause excessive muscle fatigue, was capable of regulating oxidative stress.<sup>[40]</sup>

Excessive production of nitric oxide (NO) can lead to impaired antioxidant status, altering cellular redox balance, thus causing cellular and tissue damage.<sup>[41,42]</sup> In this study, when evaluating nitrites and nitrates ( $\text{NO}_2/\text{NO}_3$ ), there was a significant increase in the production of these metabolites in the cirrhotic group compared to the control groups. The use of MLT significantly reduced  $\text{NO}_2/\text{NO}_3$  levels.<sup>[8]</sup> When observing the results, physical exercise through swimming had the ability to develop compensation for oxidative stress, increasing resistance to this condition.

The onset and progression of the inflammatory condition in several non-communicable chronic diseases are associated with increased activity and expression of NF- $\kappa$ B. This transcription factor is indicated as a mediator of the inflammatory response by increasing the synthesis of TNF- $\alpha$ . Cellular exposure to energetic substrates, such as free fatty acids, as well as stressful metabolic stimuli, such as cytokines, endotoxins, and oxidative stress, are trigger factors for the initiation of pro-inflammatory NF- $\kappa$ B signaling.<sup>[43,44]</sup> The increase in TNF- $\alpha$  and NF- $\kappa$ B expression is related to acute and chronic inflammatory processes. Therefore, it was observed the role of MLT and physical exercise in controlling the inflammatory process. Treatment with MLT in this study significantly reduced the expression of these proteins, corroborating other studies.<sup>[5,8,45]</sup> Physical exercise can mediate anti-inflammatory effects through several pathways, including downregulation of Toll-like receptors and inhibition of TNF- $\alpha$  production.<sup>[46]</sup> MLT and EX appear to be effective in reducing the production of TNF- $\alpha$  in the muscle of cirrhotic rats.<sup>[15]</sup> Administration of melatonin suppresses inflammatory processes by stimulating anti-inflammatory molecules.

Oxidative stress and inflammation are two closely related processes. Imbalance in ROS production correlates with an increase in inflammatory mediators such as TNF- $\alpha$  and NF- $\kappa$ B and leads to a chronic inflammatory state that creates a cycle where oxidative stress and inflammation feed each other.<sup>[47]</sup> facts also observed in this work. Inflammation also affects the anabolic-catabolic balance in skeletal muscle cells, causing a shift towards catabolism, atrophy, and the progression of sarcopenia, which is a major contributor to functional decline and frailty.

## Conclusion

The results obtained in the present study suggest that physical exercise with swimming was efficient to promote an improvement in the hepatic parenchyma, which makes us assume that it can be effective as a possible treatment to prevent or reduce the deleterious effects of cirrhosis. The antioxidant MLT and physical exercise were effective against the damage evaluated in this experimental model, corroborating other authors who demonstrated the benefit of different treatments. Treatment with MLT antioxidant or performing physical exercise through swimming was effective on oxidative stress and inflammation in cirrhotic liver. Treatments with melatonin and physical exercise promoted a reduction in LPO, restoration of the antioxidant system, and reduction of inflammatory mediators. According to the results of this investigation, melatonin and physical exercise were effective in restoring the different patterns evaluated in this experimental model.

**Ethics Committee Approval:** The research project was approved by the Federal University of Rio Grande do Sul Ethics Committee on Animal. All procedures were performed in accordance with Federal Law No. 11.794 of October 8, 2008, which regulates the use of animals in scientific research.

**Author Contributions:** Concept – GSM, NPM, CGSR; Design – GSM, NPM, EGS, JRC, CGSR; Supervision – GSM, NPM, EGS; Materials – GSM, EGS, SRF, NPM, MSB, JRC, MOE; Data Collection and/or Processing – GSM, EGS, SRF, NPM; Analysis and/or Interpretation – GSM, NPM; Literature Search – GSM, EGS, SRF; Writing – GSM; Critical Reviews – GSM, EGS, SRF.

**Conflict of Interest:** The authors have no conflict of interest to declare.

**Use of AI for Writing Assistance:** Not declared.

**Financial Disclosure:** The authors declared that this study has received no financial support.

**Peer-review:** Externally peer-reviewed.

## References

1. Elsharkawy AM, Oakley F, Mann DA. The role and regulation of hepatic stellate cell apoptosis in reversal of liver fibrosis. *Apoptosis* 2005;10(5):927-939. [\[CrossRef\]](#)
2. Schuppan D; Afdhal NH. Hepatic cirrhosis. *Lancet* 2008;371(9615):838-851. [\[CrossRef\]](#)
3. Bona S, Moreira AJ, Rodrigues GR, Cerski CT, Silveira TR, Marroni CA, et al. Diethylnitrosamine induced cirrhosis in wistar rats: an experimental feasibility study. *Protoplasma* 2014;252(3):825-833. [\[CrossRef\]](#)
4. Friedman SL. Mechanisms of hepatic fibrogenesis. *Gastroenterology* 2008;134:1655-1669. [\[CrossRef\]](#)
5. Colares JR, Schemitt EG, Hartmann RM, Licks F, Soares MC, Bosco AD, et al. Antioxidant and anti-inflammatory action of melatonin in an experimental model of secondary biliary cirrhosis induced by bile duct ligation. *World Journal of Gastroenterology* 2016;28(40):8918-8928. [\[CrossRef\]](#)
6. Kountouras J, Billing BH, Scheuer PJ. Prolonged bile duct obstruction: a new experimental model for cirrhosis in the rat. *Arch Br J Exp Pathol* 1984;65(3):305-311.
7. Vieira EK, Bona S, Naso FCD, Porawski M, Tiepo J, Marroni NP. Quercetin treatment ameliorates systemic oxidative stress in cirrhotic rats. *ISRN Gastroenterology* 2011;2011:604071. [\[CrossRef\]](#)
8. Colares JR, Hartmann RM, Schemitt EG, Fonseca SRB, Brasil MS, Picada JN, et al. Melatonin prevents oxidative stress, inflammatory activity, and DNA damage in cirrhotic rats. *World J Gastroenterol* 2022;28(3):348-364.
9. Dhaliwal A, Towey J, Senhor JM, Armstrong M, Elsharkawy AM. Nutrition in liver cirrhosis: a case-based overview. *Front Gastroenterol* 2020;11(2):155-161. [\[CrossRef\]](#)
10. Keating SE, Hackett DA, Parker HM, TO'Connor H, Gerofi JA, Sainsbury A, et al. Effect of aerobic exercise training dose on liver fat and visceral adiposity. *J Hepatol* 2015;63(1):174-182. [\[CrossRef\]](#)
11. Maganhin CC, Carbonel AA, Hatty JH, Fuchs LF, Oliveira-Júnior IS, Simões Mde J, et al. Efeitos da melatonina no sistema genital feminino: breve revisão [Melatonin effects on the female genital system: a brief review]. *Rev Assoc Med Bras* (1992). 2008;54(3):267-271. [\[CrossRef\]](#)
12. Rosa DP, Bona S, Simonetto D, Zettler C, Marroni CA, Marroni NP. Melatonin protects the liver and erythrocytes against oxidative stress in cirrhotic rats. *Gastroenterol Arch* 2010;47(1):72-78. [\[CrossRef\]](#)
13. Duarte-Rojo A, Ruiz-Margáin A, Montaña-Loza AJ, Macías-Rodríguez RU, Ferrando A, Kim WR. Exercise and physical activity for patients with end-stage liver disease: improving functional status and sarcopenia while on the transplant waiting list. *Trans Rev* 2018;24(1):122-139. [\[CrossRef\]](#)
14. Bertolini GRF, Nascimento CM, Artifon EL, Cunha DM, Meireles A. Swimming training on the functional evaluation of sciatic nociception in rats. *Brazil J Rheumatol* 2011;51(3):249-259. [\[CrossRef\]](#)
15. Rosa CGS, Colares JR, Fonseca SRB, Martins GS, Miguel FM, Dias AS, et al. Sarcopenia, oxidative stress and inflammatory process in muscle of cirrhotic rats – Action of melatonin and physical exercise. *Exp Mol Pathol* 2021;121:104662. [\[CrossRef\]](#)
16. Grigorov I, Bogojević D, Jovanović S, Petrović A, Ivanović-Matić S, Zolotarevski L, et al. Hepatoprotective effects of melatonin against proneurotic cellular events in streptozotocin-induced diabetic rats. *J Physiol Biochem* 2014;70(2):441-450. [\[CrossRef\]](#)
17. Bradford MM. A rapid and sensitive method for the quantitation of microgram quantities of protein utilizing the principle of protein-dye binding. *Analytical biochemistry*. 1976;7:2:248-254. [\[CrossRef\]](#)
18. Mírza HP, Fridovich I. The role of superoxide anion in the autoxidation of epinephrine and a simple assay for superoxide dismutase. *J Biol Chem* 1972;247(10):3170-3175. [\[CrossRef\]](#)
19. Buege JÁ, Aust SD. Microsomal lipid peroxidation. *Methods Enzymol* 1978;52:302-310. [\[CrossRef\]](#)
20. Flohe L, Gunzler WA. Assays of glutathione peroxidase. *Methods Enzymol* 1984;105:114-121. [\[CrossRef\]](#)



21. Boveris A, Chance B. The mitochondrial generation of hydrogen peroxide. General properties and effect of hyperbaric oxygen. *Biochem J* 1973;134(3):707-716. [\[CrossRef\]](#)
22. Granger DL, Anstey NM, Miller WC, Weinberg JB. Measuring nitric oxide production in human clinical studies. *Methods Enzymol*
23. Tice RR; Agurell E; Anderson D, Burlinson B, Hartmann A, Kobayashi H et al. Single cell gel/comet assay: guidelines for in vitro and in vivo genetic toxicology testing. *Environ Mol Mutagen* 2000;35(3):206-221. [\[CrossRef\]](#)
24. Fernandes A, Mies S. Portal hypertension. In: ROBE (Ed.) *Experimental research models in surgery*. São Paulo, Silva, OC; Zucoloto S, 1998.
25. Vercelino R, Tieppo J, Dias AS, Marroni CA, Garcia E, Meurer L, et al. N-acetylcysteine effects on genotoxic and oxidative stress parameters in cirrhotic rats with hepatopulmonary syndrome. *Basic Clin Pharmacol Toxicol* 2008;102(4):370-376. [\[CrossRef\]](#)
26. Tieppo J, Cuevas MJ, Vercelino R, Tuñón MJ, Marroni NP, González Gallego J. Quercetin administration ameliorates pulmonary complications of cirrhosis in rats. *J Nutr* 2009;139(7):1339-1346. [\[CrossRef\]](#)
27. Bosco AD, Schedler FB, Colares JR, Schemitt EG, Hartmann RM, Forgiarini Júnior AL. Melatonin effects on pulmonary tissue in the experimental model of Hepatopulmonary Syndrome. *Brazil J Pulmonol* 2019;45(3):20170164.
28. Reiter RJ, Mayo JC 2, Tan DX, Sainz RM, Alatorre-Jimenez M, Qin L. Melatonin as an antioxidant: under promises but over delivers. *J Pineal Res* 2016;61(3):253-278. [\[CrossRef\]](#)
29. Cheung K; Lee SS; Raman M. Prevalence and mechanisms of malnutrition in patients with advanced liver disease, and nutrition management strategies. *Clin Gastroenterol Hepatol* 2012;10(2):117-125. [\[CrossRef\]](#)
30. Bhanji RA, Carey EJ, Yang L, Watt KD. The Long winding road to transplant: How sarcopenia and debility impact morbidity and mortality on the waitlist. *Gastroenterol Hepatol* 2017;15(10):1492-1497. [\[CrossRef\]](#)
31. Latief U, Umar MF, Ahmad R. Nrf2 protein as a therapeutic target during diethylnitrosamine-induced liver injury ameliorated by  $\beta$ -carotene-reduced graphene oxide ( $\beta$ C-rGO) nanocomposite. *International J Biol Macromol* 2019;37:346-357. [\[CrossRef\]](#)
32. Oleshchuk O, Ivankiv Y, Falfushynska H, Mudra A, Lisnychuk N. Hepatoprotective effect of melatonin in toxic liver injury in rats. *Medicina* 2019;55(6):304. [\[CrossRef\]](#)
33. Bona S, Filippin LI, Di Naso FC, de David C, Valiatti B, Isoppo Schaun M, et al. Effect of antioxidant treatment on fibrogenesis in rats with carbon tetrachloride-induced cirrhosis. *ISRN Gastroenterology* 2012;2012:762920.
34. Van der Windt DJ, Sud V, Zhang H, Tsung A, Huang H. The Effects of Physical Exercise on Fatty Liver Disease. *The Journal of Liver Research* 2018;18(2):89-101. [\[CrossRef\]](#)
35. Shojae-Moradie F, Cuthbertson DJ, Barrett M, Jackson NC, Arenque R, Thomas EL, et al. *The Journal of Clinical Endocrinology and Metabolism*. 2016;101:4219-4228. [\[CrossRef\]](#)
36. Salvi JO, Schemitt EG, Colares JR, Hartmann RM, Marroni CA, Marroni NP. Action of Melatonina on Severe Acute Liver Failure in Rats. *Journal of Pharmacy and Biological Sciences* 2017;12(3)62-75. [\[CrossRef\]](#)
37. Amália PM, Possa MN, Augusto MC, Francisca LS. Quercetin prevents oxidative stress in cirrhotic rats. *Dig Dis Sci* 2007;52(10):2616-2621. [\[CrossRef\]](#)
38. Rodrigues LO, Oliveira A, Lima NR, Machado-Moreira CA. Heat storage rate and acute fatigue in rats. *Brazil J Med Biol Res* 2003;36(1):131-135.
39. Neto JAS, De Castro BF. Melatonin, biological rhythms and sleep – a literature review. *Brazil J Neurol* 2008;44(1):5-11.
40. Thirupathi A, Souza CT. Multi-regulatory network of ROS: the interconnection of ROS, PGC-1  $\alpha$ , and AMPK-SIRT1 during exercise. *J Physiol Biochem* 2017;73(4):487-494. [\[CrossRef\]](#)
41. Marzetti E, Calvani R, Cesari M, Buford TW, Lorenzi M, Behnke BJ, et al. Mitochondrial dysfunction and sarcopenia of aging: from signaling pathways to clinical trials. *Int J Biochem Cell Biol* 2013;45(10):2288-2301. [\[CrossRef\]](#)
42. Iwakiri Y, Kim MY. Nitric oxide in liver diseases. *Trends Pharmacol Sci* 2015;36(8):524-536. [\[CrossRef\]](#)
43. Li H, Horke S, Förstermann U. Vascular oxidative stress, nitric oxide and atherosclerosis. *Atherosclerosis* 2014;237(1):208-219. [\[CrossRef\]](#)
44. Antunes BMM, Caires SU, Lira FS, Fernandes RA. Arterial thickness and immunometabolism: The mediating role of chronic exercise. *Curr Cardiol Rev* 2016;12(1):47-51. [\[CrossRef\]](#)
45. Bona S, Rodrigues G, Moreira AJ, Di Naso FC, Dias AS, Silveira TR. Antifibrogenic effect of melatonin in rats with experimental liver cirrhosis induced by carbon tetrachloride. *JGH Open* 2018;2(4):117-123. [\[CrossRef\]](#)
46. Meng SJ, Yu LJ. Oxidative stress, molecular inflammation and sarcopenia. *Int J Mol Sci* 2010;11(4):1509-1526. [\[CrossRef\]](#)
47. Cannataro R, Carbone L, Petro JL, Cione E, Vargas S, Angulo H, et al. Sarcopenia: Etiology, nutritional approaches, and mirnas. *Int J Mol Sci* 2021;22:9724. [\[CrossRef\]](#)