

# Comparison of the recommendation of international autoimmune hepatitis pathology group 2022 and the simplified criteria for autoimmune hepatitis 2008: A preliminary study

Kenan Moral<sup>1</sup>, Berkay Simsek<sup>2</sup>, Veysel Baran Tomar<sup>3</sup>, Cihad Albayrak<sup>3</sup>, Mustafa Ergin<sup>1</sup>, Guner Kilic<sup>1</sup>, Ali Karatas<sup>1</sup>, Nergiz Ekmen<sup>1</sup>, Murat Kekilli<sup>1</sup>, Mehmet Ibis<sup>1</sup>, Tarkan Karakan<sup>1</sup>, Mehmet Cindoruk<sup>1</sup>, Guldal Esendagli<sup>2</sup>, Gulen Akyol<sup>2</sup>

<sup>1</sup>Department of Gastroenterology and Hepatology, Gazi University School of Medicine, Ankara, Turkiye; <sup>2</sup>Department of Pathology, Gazi University School of Medicine, Ankara, Turkiye; <sup>3</sup>Department of Internal Medicine, Gazi University School of Medicine, Ankara, Turkiye

## Abstract

**Background and Aim:** The histological diagnosis of autoimmune hepatitis (AIH) is challenging. A new consensus recommendation was provided by the International AIH Pathology Group to address the problems in the histological diagnosis. The purpose of this study is to compare the 2008 'simplified' criteria for AIH with the 'consensus recommendation' of 2022 in terms of diagnostic sensitivity.

**Materials and Methods:** A retrospective analysis was conducted on pathological specimens of patients diagnosed with Autoimmune Hepatitis (AIH) between 2010 and 2022. Out of 188 patients enlisted, 88 were selected based on exclusion criteria. The specimens were examined by two experienced hepatopathologists and a resident pathologist. All specimens were analyzed using both the "simplified" criteria and the new consensus recommendations.

**Results:** Out of a total of 78 patients, the 2022 consensus recommendations raised the diagnostic category of 16 patients (20.5%) to a higher level. Six patients who were previously diagnosed as "atypical" were now considered "possible AIH", while 10 patients with a "compatible" diagnosis were elevated to "likely AIH" category. No patients were found to fall into a lower diagnostic category according to the new recommendations. A significant difference in diagnostic sensitivity was observed between the 2008 criteria and the 2022 consensus report ( $p < 0.001$ ).

**Conclusion:** The 2022 consensus recommendation may be more sensitive in the diagnosis of AIH in comparison to the 2008 'simplified' histological criteria. More studies are needed both for the validation of the sensitivity of the new consensus recommendation and for the determination of the specificity.

**Keywords:** Autoimmune hepatitis; consensus recommendation for autoimmune hepatitis; drug-induced-liver-injury; interface hepatitis; simplified criteria for autoimmune hepatitis.

**How to cite this article:** Moral K, Simsek B, Tomar VB, Albayrak C, Ergin M, Kilic G, et al. Comparison of the recommendation of international autoimmune hepatitis pathology group 2022 and the simplified criteria for autoimmune hepatitis 2008: A preliminary study. *Hepatology Forum* 2024; 5(3):100–105.

**Received:** October 31, 2023; **Revised:** November 15, 2023; **Accepted:** November 29, 2023; **Available online:** July 02, 2024

**Corresponding author:** Kenan Moral; Gazi Universitesi Tip Fakultesi, Gastroenteroloji ve Hepatoloji Anabilim Dalı, Ankara, Turkiye  
**Phone:** +90 312 202 58 99; **e-mail:** kenanaan.moral@gmail.com



OPEN ACCESS  
This work is licensed under a Creative Commons Attribution-NonCommercial 4.0 International License.

*Hepatology Forum* - Available online at [www.hepatologyforum.org](http://www.hepatologyforum.org)

## Introduction

Autoimmune hepatitis (AIH) is an immune-mediated disease of the liver characterized by hypergammaglobulinemia, specific autoantibodies, and features on liver biopsy.<sup>[1]</sup> Although it is a rare disease, its incidence and prevalence are increasing worldwide.<sup>[2]</sup> AIH can manifest at any age, from infancy to late adulthood. The clinical spectrum is heterogeneous, ranging from mild liver enzyme elevation to acute liver failure. The specific diagnosis of AIH relies on histopathological findings, laboratory values, and the clinical history of the patient. It is also very challenging to distinguish AIH from toxic hepatitis, viral hepatitis, or Wilson's disease, which share similar pathological and serological features.<sup>[3]</sup>

Scoring systems like the 'simplified' or the 'revised' version of the 'original' score for AIH were developed to aid in the diagnosis of AIH.<sup>[4]</sup> Liver histology plays an essential role in these scores and is mandatory for the diagnosis of AIH. Early histological classification criteria were solely based on chronic hepatitis, usually featuring portal-based lymphoplasmacytic inflammation and interface hepatitis.<sup>[5]</sup> However, the acute presentation of AIH, which includes lobular-based inflammation together with centrilobular necrosis lacking portal/periportal histological features of chronic hepatitis, will be overlooked or designated as drug-induced or toxic acute liver injury.<sup>[6]</sup> Although the histological criteria for AIH have been applied for many years, these criteria were neither confirmed nor validated by prospective studies or any international consensus statement.

Due to these weak points, the European Reference Network on Hepatological Diseases and the European Society of Pathology have released a new consensus recommendation for the histological criteria of AIH to increase the sensitivity and specificity of AIH diagnosis.<sup>[7]</sup> According to the 2008 simplified criteria, histological findings were classified as "typical (score 2)," "compatible (score 1)," and "atypical (score 0)" for AIH [8]. Distinct from the 2008 simplified histologic scoring, according to the 2022 recommendations of the International AIH Pathology Working Group, biopsies are initially classified as either portal or lobular-based hepatitis and then categorized as "likely," "possible," or "unlikely" for AIH.<sup>[7]</sup>

In this study, our aim is to evaluate both the diagnostic accuracy and differences between the 2008 simplified criteria and the 2022 recommendations of the International AIH Pathology Working Group.

## Materials And Methods

AIH between 2010 and 2022 were retrospectively analyzed. The main enrollment criteria included: (1) the presence of a ‘naive’ (initial) biopsy before receiving any treatment, (2) availability and thorough documentation of the patient’s treatment protocol and regular follow-up, and (3) absence of any other known primary cholestatic disease suggesting overlap syndrome. All cases were re-evaluated by two senior hepatopathologists and a resident pathologist. Furthermore, age, sex, age at diagnosis, serological markers, pretreatment liver enzyme levels, liver function tests, and immunoglobulin levels were analyzed. According to criteria (1) and (2), 88 out of 180 patients were enrolled in the study, with 88 cases re-evaluated. Patients with overlap syndrome (n=10) were excluded from the study, leaving only 78 patients for analysis. The patient flowchart of the study is summarized in Figure 1.

## Histopathological Evaluation

78 biopsies stained with hematoxylin and eosin, Masson’s trichrome, and methyl-green pyronin were re-evaluated. Additional histochemical (rhodanin, periodic-acid Schiff, periodic-acid-Schiff with diastase, Congo red, and gentian violet) and immunohistochemical staining (cytokeratin 19, IgG, and IgG4) were performed if needed for the purpose of differential diagnosis. All cases were blindly examined according to histologic features of both the 2008 simplified histological criteria for the diagnosis of AIH and the 2022 consensus report of the International AIH Pathology Group workshop. According to the 2008 Simplified Criteria, histological findings were classified as “typical (score 2),” “compatible (score 1),” and “atypical (score 0)” for AIH.<sup>[8]</sup> Biopsies that showed all three features: (1) interface hepatitis with portal lymphocytic/lymphoplasmacytic infiltration, (2) emperipolesis, defined as the presence of intact lymphocyte/plasma cells in the hepatocyte cytoplasm, and (3) hepatic rosette formation, defined as the lining up of hepatocytes around clear lumina-like spaces, were considered typical. Biopsies lacking all histologic features were considered atypical, while those with a chronic hepatitis pattern of injury with lymphocytic infiltration were classified as compatible. Biopsies showing signs of other primary liver diseases were classified as atypical for AIH.

Distinct from the 2008 simplified histological scoring, according to the 2022 recommendations of the International AIH Pathology Working Group, biopsies were initially classified as either portal (chronic) or lobular (acute) hepatitis based on the localization of predominant inflammation. Then all biopsies with either portal or lobular hepatitis were classified as “likely,” “possible,” or “unlikely” AIH in conjunction with the criteria. The presence of plasma cells was evaluated semi-quantitatively. A plasma cell cluster was defined as  $\geq 5$  plasma cells in any foci of the portal and/or lobular area.

The term mild inflammatory activity is described accurately according to Ishak’s modified Histological Activity Index (mHAI) as suggested by Lohse et al.<sup>[7]</sup> as follows: for category A (periportal or periseptal interface hepatitis)  $mHAI \leq 1$ , for category B (confluent necrosis)  $mHAI = 0$ , and for category C (focal spotty/lytic necrosis, apoptosis, and focal inflammation)  $mHAI \leq 2$ . Ishak staging was used to evaluate fibrosis (stage 0–6). Additionally, we created a checklist for each detected parameter (Fig. 2). First, biopsies were investigated for any histological findings indicative of a disease other than AIH. The presence of portal lymphoplasmacytic inflammation, interface activity, rosette formation, emperipolesis, and lobular activity/lobular lymphoplasmacytic inflammation was noted. Based on these find-

ings, biopsies were classified using the 2008 Simplified Histologic Scoring and the 2022 Recommendations of the International AIH Pathology Working Group. Biopsies were also classified as acute, subacute, or chronic hepatitis, in accordance with the presence of fibrosis. The presence or absence of plasma cells in the interfacial activity zone was recorded. Any number of plasma cells in the areas of lobular necroinflammatory activity is accepted as “plasma cell presence in lobular area” and the highest number of plasma cells in any foci of lobular activity was counted. The presence of plasma cell “clusters” in the lobular areas was also noted.

## Statistical Analysis

Data analysis was conducted using the IBM SPSS 26.0 package program. The conformity of the variables to the normal distribution was evaluated using the Shapiro-Wilk test. Numbers and percentages were used to define categorical variables, mean ( $\pm$ standard deviation) for normally distributed variables, and median (minimum–maximum) (25%–75%) for non-normally distributed variables. Chi-square or Fisher’s exact tests were used for intergroup comparisons of the categorical variables. The Mann-Whitney U test was used to compare continuous variables between the two groups. The McNemar-Bowker test was used for intra-group (dependent group) comparisons of categorical variables. The Kappa test was used to evaluate the level of agreement within the group. The linear relationship between ordinal variables was evaluated using Kendall’s tau-b correlation test. A  $p < 0.05$  was considered statistically significant.

## Results

### Baseline Characteristics

Our patients had a mean age of  $53.1 \pm 18.3$  years, and the age at diagnosis was  $45.2 \pm 18.2$  years. Of the total patients, 83.3% (n=65) were female. Table 1 shows the autoimmune serological markers and liver enzymes. There was no significant difference in both the pretreatment laboratory values and sociodemographic features between the portal and lobular hepatitis groups ( $p > 0.05$ ). Histologically, 87.2% (n=68) of our patients had portal lymphoplasmacytic inflammation, while 96.2% (n=75) had interface activity. Additionally, 74.4% (n=58) had rosette formation, and 69.2% (n=54) of the patients had emperipolesis.

### Evaluation of Fibrosis

The fibrosis score was assigned to the biopsies using ISHAK scoring and Masson’s Trichrome Stain. The median fibrosis score was 2/6. Nine patients had a score of 0/6, 11 patients had 1/6, 23 patients had 2/6, 12 patients had 3/6, 9 patients had 4/6, 3 patients had 5/6, and 4 patients had 6/6 fibrosis scores.

### Accompanying Concomitant Diseases Together with AIH

Out of 29 cases that were suspected to be AIH, 19 cases showed histological features of other diseases besides the features that indicated the possibility of AIH. The most common features that indicated the possibility of another disease were steatosis, acute cholestasis, and bilirubinostasis (Table 2). Biopsies that showed chronic cholestasis with bile duct damage, in addition to hepatic damage, were excluded as they could potentially overlap with primary biliary cholangitis or primary sclerosing cholangitis.

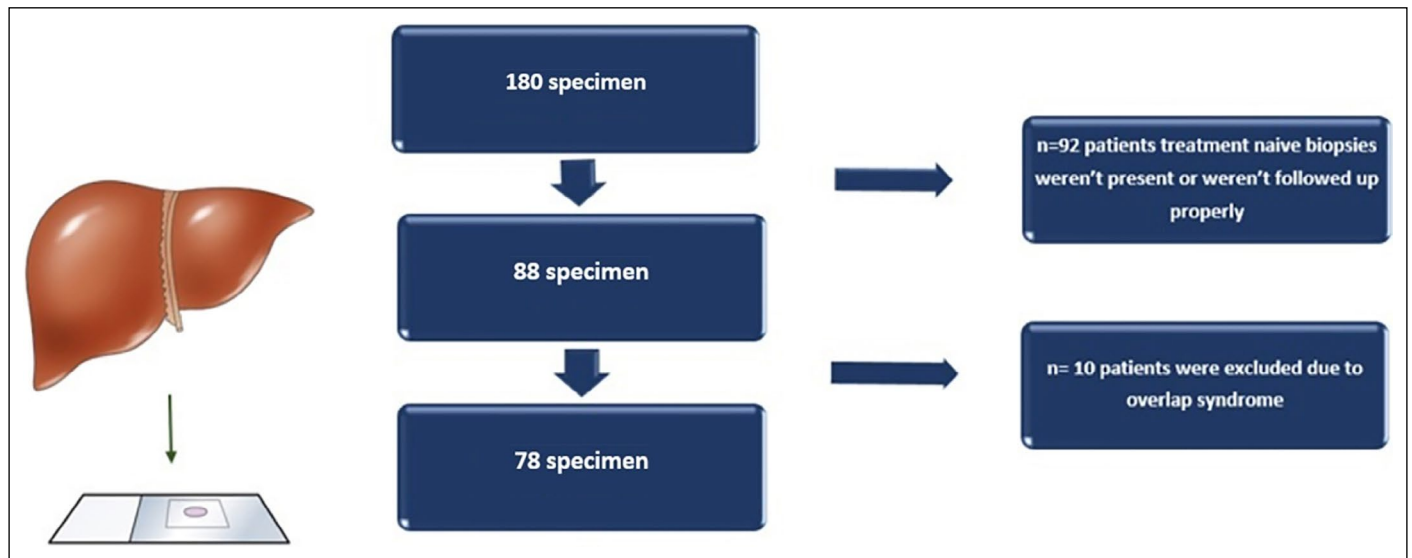


Figure 1. Flow-Chart of the patients which were selected for the study.

2008	2022-Portal based	2022-Lobular based
<b>TYPICAL-SCORE 2</b>	<input type="checkbox"/> Portal lymphoplasmacytic inflammation	<input type="checkbox"/> Loblar lymphoplasmacytic inflammation
<input type="checkbox"/> Portal lymphoplasmacytic inflammation	<input type="checkbox"/> Interface activity	<input type="checkbox"/> Portal inflammation
<input type="checkbox"/> Interface activity	<input type="checkbox"/> Lobular activity	<input type="checkbox"/> Portal-based fibrosis
<input type="checkbox"/> Rosette formation	<input type="checkbox"/> Presence of feature of another liver disease	<input type="checkbox"/> Interface activity
<input type="checkbox"/> Emperipolesis	RESULT:	<input type="checkbox"/> Presence of feature of another liver disease
<b>COMPATIBLE- SCORE 1</b>	LIKELY- POSSIBLE- UNLIKELY	RESULT:
<input type="checkbox"/> Chronic Interface hepatitis		LIKELY-POSSIBLE-UNLIKELY
<b>ATYPICAL- SCORE 0</b>		
<input type="checkbox"/> Presence of feature of another liver disease		
<b>ACUTE</b>	<b>TRICHROME-FIBROSIS</b>	<b>MGP-PLASMA CELLS</b>
<b>SUBACUTE</b>		<input type="checkbox"/> Portal (≥%10)
<b>CHRONIC</b>		<input type="checkbox"/> Lobular(Cluster□ Number:....)
		<input type="checkbox"/> Interface
		<b>OTHER FEATURES</b>

Figure 2. Detailed checklist for each parameter to be detected during the pathological evaluation.

**Comparison of the Simplified Criteria with the New Consensus Statement**

According to the 2008 criteria, 9 of 78 patients (11.5%) were given a score of “0” (atypical), while 33 (42.3%) were given a score of “1” (compatible), and 36 (46.2%) were given a score of “2” (typical). According to the 2022 consensus recommendations, 60 patients (76.9%) were initially diagnosed with portal hepatitis, and 18 patients (23.1%) were diagnosed with lobular hepatitis. Three (3.8%) patients were clas-

sified as unlikely, 29 (37.2%) as possible, and 46 (59.0%) as likely. In the portal hepatitis group, three (5.0%) were classified as unlikely, 23 (38.3%) as possible, and 34 (43.7%) as likely, while in the lobular hepatitis group, zero were classified as unlikely, six as possible, and twelve as likely AIH. When the 2008 criteria and the 2022 recommendations were evaluated, compatibility was found in 62 patients (79.5%) (Table 3). Sixteen patients (20.5%) were elevated to the upper category according to the 2022 consensus recommendations, while none were

**Table 1.** Baseline demographic and laboratory values of the patients

Variable	Total (n=78)		Portal hepatitis		Lobular hepatitis		p
	n	%	n	%	n	%	
Age (year)*	53.1±18.3		51.8±18.7		57.4±16.6		0.255 <sup>c</sup>
Age of diagnosis (year)*	45.2±18.2		44.2±18.8		48.4±16.1		0.392 <sup>c</sup>
Gender (female)	65	83.3	50	83.3	15	83.3	1.0 <sup>b</sup>
ANA	55	85.9	45	88.2	10	76.9	0.372 <sup>b</sup>
ANTI-LKM-1	8	13.3	4	8.7	4	28.6	0.077 <sup>b</sup>
AMA	12	18.5	11	22.0	1	6.7	0.267 <sup>b</sup>
ANTI-LC1	2	3.4	2	4.4	0	0.0	1.0 <sup>b</sup>
ANTI-SLA	4	7.4	4	9.5	0	0.0	0.564 <sup>b</sup>
Anti-sp100	2	5.9	2	6.9	0	0.0	1.0 <sup>b</sup>
Anti-gp210	2	6.1	2	7.1	0	0.0	1.0 <sup>b</sup>
ASMA	11	24.4	10	27.0	1	12.5	0.657 <sup>b</sup>
P-ANCA	8	27.6	5	20.8	3	60.0	0.112 <sup>b</sup>
ALT**	283 (17–2823)		191 (17–1500)		603 (23–2823)		0.120 <sup>c</sup>
AST**	201 (18–21550)		166 (18–21550)		436 (27–3683)		0.499 <sup>c</sup>
ALP**	155 (54–925)		153 (54–925)		165 (68–474)		0.333 <sup>c</sup>
GGT**	132 (7–1050)		118 (7–512)		156 (20–1050)		0.532 <sup>c</sup>
Albumin**	3.8 (2.2–41.0)		3.8 (2.2–5.1)		3.6 (2.8–41.0)		0.821 <sup>c</sup>
Bilirubin**	1.4 (0.2–27.6)		1.2 (0.2–27.6)		2.9 (0.4–25.6)		0.275 <sup>c</sup>
INR**	1.1 (0.8–1.8)		1.1 (0.9–1.8)		1.1 (0.8–1.5)		0.765 <sup>c</sup>
IgG**	2155 (110–7760)		2180 (876–7760)		1930 (110–6580)		0.249 <sup>c</sup>
IgM**	200 (56–900)		199 (56–900)		224 (89–476)		0.554 <sup>c</sup>
IgA**	272 (118–1080)		272 (119–1080)		263 (118–673)		0.854 <sup>c</sup>
Lobular activity	70	89.7	52	86.7	18	100.0	0.187 <sup>b</sup>
Portal lymphoplasmacytic inflammation	68	87.2	55	91.7	13	72.2	0.045 <sup>b</sup>
Interface activity	75	96.2	59	98.3	16	88.9	0.131 <sup>b</sup>
Rosette formation	58	74.4	46	76.7	12	66.7	0.539 <sup>b</sup>
Emperipolesis	54	69.2	41	68.3	13	72.2	0.754 <sup>a</sup>
Portal plasma presence	72	92.3	57	95.0	15	83.3	0.132 <sup>b</sup>
Interface plasma presence	57	73.1	46	76.7	11	61.1	0.230 <sup>b</sup>
Lobular plasma number**	5 (0–32)		3.5 (0–16)		6.5 (0–32)		0.025 <sup>c</sup>

\*: Mean±standard deviation; \*\*: Median 25%-75%; <sup>a</sup>: ki kare; <sup>b</sup>: Fisher's exact; <sup>c</sup>: Mann Whitney U were used for statistical analysis. ANA: Anti-nuclear antibody; Anti-LKM-1: Anti-liver kidney microsomal antibody; AMA: Anti-mitochondrial antibody; ANTI-LC1: Anti-liver cystol antibody; ANTI-SLA: Anti soluble liver antigen antibody; Anti-sp100: Anti-sp100 antibody; Anti-gp210: Anti-gp210 antibody; ASMA: Anti-smooth muscle antibody; P-ANCA: Perinuclear anti-neutrophilic cytoplasmic antibodies; ALT: Alanine aminotransferase; AST: Aspartate aminotransferase; ALP: Alkaline phosphatase; GGT: Gamma-glutamyltransferase; INR: Internationalized normalized ratio; IgG: Immunoglobulin G; IgM: Immunoglobulin M; IgA: Immunoglobulin A.

**Table 2.** Accompanying features of “Likely” AIH patients who had suggestive features of another disease

	Steatosis	Acute cholestasis/ billirubinostasis	Suppurative	Granulomas cholangitis	Microgranulomas	Hemochromatosis	Hepatitis B
n	7	4	2	2	2	1*	1**

\*: Patient had Grade 2/4 iron deposition according to Scheuer's grading and a family history of hemochromatosis; \*\*: Patient had serological and immunohistochemical of HBV infection. AIH: Autoimmune hepatitis; HBV: Hepatitis B virus.

found to fall into the lower category. Six patients with a score of “0” assessed by the 2008 criteria were raised to the “possible AIH” category according to the 2022 consensus recommendations, and 10 patients with a score of “1” were raised to the “likely AIH” category. There

were statistically significant differences between the 2008 and 2022 consensus reports regarding diagnostic sensitivity. The 2022 consensus report was more sensitive for both diagnosis and histological grading ( $p<0.001$ ). Of the six patients in the possible category, five were diag-

**Table 3.** Comparison of the biopsies regarding the diagnostic staging and the compliance level between the 2008 criteria and 2022 consensus recommendation

2008 criteria definition	2022 consensus definition									
	Unlikely			Possible			Likely			Total
	Portal	Lobular	Total	Portal	Lobular	Total	Portal	Lobular	Total	
“0”, atypical	3	0	3	5	1	6	0	0	0	9
“1”, compatible	0	0	0	18	5	23	6	4	10	33
“2”, typical	0	0	0	0	0	0	28	8	36	36
Total	3	0	3	23	6	29	34	12	46	78
Mc Nemar Bowker (total)	p<0.001									
Kappa test										
Lobuler	(kappa value=0.483)			p=0.016						
Portal	(kappa value=0.681)			p<0.001						
Total	(kappa value=0.638)			p<0.001						

nosed with portal hepatitis, while one had lobular hepatitis. Six of the ten patients in the likely category were diagnosed with portal hepatitis, while four were diagnosed with lobular hepatitis. Furthermore, there was moderate statistical agreement (kappa=0.638) between the two histological staging systems (p<0.001). Regarding lobular hepatitis, there was low to medium agreement between the 2008 and 2022 classifications (kappa=0.483, p=0.016), while there was moderate agreement regarding portal hepatitis (kappa=0.681, p<0.001) (Table 3).

**Discussion**

This study is the first of its kind to apply the new consensus recommendation retrospectively and compare it with the previous 2008 simplified criteria. Our findings showed a statistically significant difference between the 2008 simplified criteria and the 2022 consensus report concerning diagnostic accuracy (p<0.001). The 2022 consensus recommendations elevated sixteen patients (20.5%) to the upper category, while none were found to fall into the lower category. Additionally, six patients who were categorized as atypical based on the 2008 criteria were elevated to the “possible” category, and ten patients categorized as compatible were elevated to the “likely” category when analyzed according to the new consensus statement.

Upon evaluating the compatibility between the old and new criteria, it was found that there was a moderate level of agreement between the 2008 and 2022 criteria (kappa value=0.638). In the subgroup analysis, the portal hepatitis group showed moderate conformity (kappa=0.681), while the conformity in the lobular hepatitis group (kappa=0.483) was even lower. This indicates that while the new consensus statement of 2022 is more precise in the diagnosis of AIH overall, it is more accurate in the diagnosis of lobular hepatitis than the previous 2008 criteria. The improvement in diagnostic accuracy, particularly in the acute lobular hepatitis setting, is consistent with the purpose of a consensus report.<sup>[5]</sup>

Scoring systems combining clinical, laboratory, and histological findings were created to establish a diagnosis of AIH. In previous scoring systems, histologic parameters were more relevant for the chronic portal type of AIH and underestimated the predominant lobular pattern that reflects the acute presentation of AIH.<sup>[9–12]</sup> Based on the ‘Simplified Diagnostic Criteria for AIH-2008’, a chronic hepatitic pattern is defined as

‘compatible,’ while a histology showing portal lymphocytic or lymphoplasmacytic inflammation with interface activity, emperipolesis, and hepatocellular rosettes is considered ‘typical’ for AIH.<sup>[13]</sup>

According to the 2022 recommendations, the initial determination should be made regarding the dominant inflammation pattern, which can either be chronic portal hepatitis or acute lobular hepatitis. The presence of portal lymphoplasmacytic inflammation, prominence of plasma cells, and plasma cell clusters in both lobular and portal areas should be evaluated for the classification of ‘likely-possible and unlikely AIH’. However, features like hepatocellular rosettes and emperipolesis have been discarded, as they are frequent findings of severe inflammation and regeneration and can be observed in other liver diseases like viral hepatitis, drug-induced liver injury (DILI), or primary biliary cholangitis (PBC).<sup>[7,14]</sup>

The previous simplified criteria in clinical practice had low sensitivity and specificity to differentiate AIH from toxic hepatitis, viral hepatitis, and Wilson’s disease, particularly in the setting of acute hepatitis.<sup>[10]</sup> Differentiating between DILI and AIH is a major challenge in the clinical setting; there are no serological markers or pathognomonic features to differentiate between these two entities.<sup>[15]</sup> Prominent lymphoplasmacytic infiltration, interface hepatitis, and confluent necrosis, either perivenular or panacinar, are also seen in DILI, making the differentiation between AIH and DILI much more difficult.<sup>[16]</sup> In addition to advanced fibrosis, which is usually seen in AIH and less in DILI, there are no known microscopic findings that can discriminate AIH from DILI.<sup>[17,18]</sup> The new consensus statement can help solve the clinical dilemma in discriminating between AIH and DILI; however, more studies are needed to validate and enhance it.

It was found that 19 patients in the ‘possible’ AIH group had histological features of another liver disease. However, in our analysis, we removed patients with suggestive features of overlap syndrome while accepting concomitant diseases with AIH, according to both criteria. Unfortunately, our sample size was too small to compare the accuracy of the old and new criteria in cases of accompanying diseases. Therefore, more studies are needed to assess whether the new consensus recommendations can facilitate treatment decisions in such patients.

Our study had some limitations, such as the small number of evaluated histological specimens. As our study was retrospective, we only

assessed patients who were previously diagnosed with AIH. Prospective studies applying the new consensus criteria, especially in the acute hepatitis setting, are required to determine the sensitivity and specificity of the new consensus statement more effectively.

## Conclusion

Our study shows that the new consensus recommendations for the histological criteria of AIH from the International AIH Pathology Group seemed to be more sensitive in the diagnosis of both acute and chronic types of AIH. Further meta-analyses and prospective studies are needed to validate and enhance the new classification to increase the specificity and sensitivity of the new consensus recommendation.

**Ethics Committee Approval:** The Gazi University Clinical Research Ethics Committee granted approval for this study (date: 19.06.2023, number: 539).

**Author Contributions:** Concept – KM, BS, VBT, CA, ME, GK, AK, NE, MK, MI, TK, MC, GE, GA; Design – KM, BS, VBT, CA, ME, GK, AK, NE, MK, MI, TK, MC, GE, GA; Supervision – KM, BS, VBT, CA, ME, GK, AK, NE, MK, MI, TK, MC, GE, GA; Fundings – KM, BS, VBT, CA, ME, GK, AK, NE, MK, MI, TK, MC, GE, GA; Materials – KM, BS, VBT, CA, ME, GK, AK, NE, MK, MI, TK, MC, GE, GA; Data Collection and/or Processing – KM, BS, VBT, CA, ME, GK, AK, NE, MK, MI, TK, MC, GE, GA; Analysis and/or Interpretation – KM, BS, VBT, CA, ME, GK, AK, NE, MK, MI, TK, MC, GE, GA; Literature Search – KM, BS, VBT, CA, ME, GK, AK, NE, MK, MI, TK, MC, GE, GA; Writing – KM, BS, VBT, CA, ME, GK, AK, NE, MK, MI, TK, MC, GE, GA; Critical Reviews – KM, BS, VBT, CA, ME, GK, AK, NE, MK, MI, TK, MC, GE, GA.

**Conflict of Interest:** The authors have no conflict of interest to declare.

**Use of AI for Writing Assistance:** Not declared.

**Financial Disclosure:** The authors declared that this study has received no financial support.

**Peer-review:** Externally peer-reviewed.

## References

1. Liberal R, Grant CR, Mieli-Vergani G, Vergani D. Autoimmune hepatitis: a comprehensive review. *J Autoimmun* 2013;41:126-139. [\[CrossRef\]](#)
2. Tunio NA, Mansoor E, Sheriff MZ, Cooper GS, Sclair SN, Cohen SM. Epidemiology of Autoimmune Hepatitis (AIH) in the United States Between 2014 and 2019: A Population-based National Study. *J Clin Gastroenterol* 2021;55(10):903-910. [\[CrossRef\]](#)
3. European Association for the Study of the Liver. EASL Clinical Practice Guidelines: Autoimmune hepatitis. *J Hepatol* 2015;63(4):971-1004 [\[CrossRef\]](#)
4. Chandok N, Silveira MG, Lindor KD. Comparing the simplified and international autoimmune hepatitis group criteria in primary sclerosing cholangitis. *Gastroenterol Hepatol (NY)* 2010;6(2):108-112.
5. Alvarez F, Berg PA, Bianchi FB, Bianchi L, Burroughs AK, Cancado EL, et al. International Autoimmune Hepatitis Group Report: review of criteria for diagnosis of autoimmune hepatitis. *J Hepatol* 1999;31(5):929-938. [\[CrossRef\]](#)
6. Rahim MN, Miquel R, Heneghan MA. Approach to the patient with acute severe autoimmune hepatitis. *JHEP Rep* 2020;2(6):100149. [\[CrossRef\]](#)
7. Lohse AW, Sebode M, Bhathal PS, Clouston AD, Dienes HP, Jain D, et al. Consensus recommendations for histological criteria of autoimmune hepatitis from the International AIH Pathology Group: Results of a workshop on AIH histology hosted by the European Reference Network on Hepatological Diseases and the European Society of Pathology: Results of a workshop on AIH histology hosted by the European Reference Network on Hepatological Diseases and the European Society of Pathology. *Liver Int* 2022;42(5):1058-1069. [\[CrossRef\]](#)
8. Hennes EM, Zeniya M, Czaja AJ, Parés A, Dalekos GN, Krawitt EL, et al. Simplified criteria for the diagnosis of autoimmune hepatitis. *Hepatology* 2008;48(1):169-176. [\[CrossRef\]](#)
9. Gurung A, Assis DN, McCarty TR, Mitchell KA, Boyer JL, Jain D. Histologic features of autoimmune hepatitis: a critical appraisal. *Hum Pathol* 2018;82:51-60. [\[CrossRef\]](#)
10. Covelli C, Sacchi D, Sarcognato S, Cazzagon N, Grillo F, Baciocchi F, et al. Pathology of autoimmune hepatitis. *Pathologica* 2021;113(3):185-193.
11. Muratori P, Lenzi M, Cassani F, Lalanne C, Muratori L. Diagnostic approach to autoimmune hepatitis. *Expert Rev Clin Immunol* 2017;13(8):769-779.
12. Tiniakos DG, Brain JG, Bury YA. Role of Histopathology in Autoimmune Hepatitis. *Dig Dis*. 2015;33(Suppl 2):53-64. [\[CrossRef\]](#)
13. Zhang X, Jain D. The many faces and pathologic diagnostic challenges of autoimmune hepatitis. *Hum Pathol* 2023;132:114-125. [\[CrossRef\]](#)
14. de Boer YS, van Nieuwkerk CM, Witte BI, Mulder CJ, Bouma G, Bloemena E. Assessment of the histopathological key features in autoimmune hepatitis. *Histopathology* 2015;66(3):351-362. [\[CrossRef\]](#)
15. Castiella A, Zapata E, Lucena MI, Andrade RJ. Drug-induced autoimmune liver disease: A diagnostic dilemma of an increasingly reported disease. *World J Hepatol* 2014;6(4):160-168. [\[CrossRef\]](#)
16. Kleiner DE, Chalasani NP, Lee WM, Fontana RJ, Bonkovsky HL, Watkins PB. Hepatic histological findings in suspected drug-induced liver injury: systematic evaluation and clinical associations. *Hepatology* 2014;59(2):661-670.
17. Björnsson E, Talwalkar J, Treeprasertsuk S, Kamath PS, Takahashi N, Sanderson S. Drug-induced autoimmune hepatitis: clinical characteristics and prognosis. *Hepatology* 2010;51(6):2040-2048. [\[CrossRef\]](#)
18. Özaslan E, Günşar F, Çiftçibaş Örmeci A, Hatemi İ, Efe C, et al. Diagnosis and treatment of autoimmune hepatitis: Questions, answers, and illustrative cases: Endorsed by autoimmune liver diseases special interest group, Turkish Association for the Study of Liver. *Turk J Gastroenterol* 2023;34(Suppl 2):S1-S33. [\[CrossRef\]](#)